

Comparison of the Degree of Right Atrial Opacification Seen on Intracardiac Echocardiography Following Femoral or Antecubital Injection of Saline Contrast

Daniel Saura, Arcadi García-Alberola, Rafael Florenciano, Gonzalo de la Morena, Juan J. Sánchez-Muñoz, Federico Soria, Belén Redondo-Bermejo, and Mariano Valdés-Chávarri

Servicio de Cardiología, Hospital Universitario Virgen de la Arrixaca, Murcia, Spain

It is thought that femoral injection of agitated saline contrast is better for detecting patent foramen ovale than antecubital injection mainly because of the nature of intraatrial flow where the venae cavae enter the heart. Our aim was to investigate the effect of the contrast injection site on the degree of right atrial opacification seen on intracardiac echocardiography. The degree of right atrial opacification after each femoral or antecubital injection of saline contrast was scored from 0-4 in 21 patients. It was shown that the degree of right atrial opacification was greater after femoral than antecubital injection (3.76 vs 1.62; $P < .001$). Future studies comparing the 2 routes of saline contrast injection should control for the degree of right atrial opacification.

Key words: Contrast echocardiography. Intravascular ultrasonography. Foramen ovale. Veins.

Comparación del grado de opacificación auricular derecha con ecocardiografía intracardiaca tras inyecciones femoral y antecubital de contraste salino

Se asume que la superioridad de la inyección femoral de suero salino agitado para la detección del foramen oval permeable comparada con la antecubital se debe principalmente al efecto de las corrientes intraauriculares de la desembocadura de las cavas. Nos propusimos evaluar la influencia del lugar de inyección de contraste en el grado de opacificación auricular derecha en ecografía intracardiaca. Se puntuó de 0 a 4 el grado de opacificación obtenido tras inyecciones venosas por vía antecubital y femoral de contraste salino en 21 pacientes. Se comprobó que el grado de opacificación auricular derecha es mayor tras la inyección femoral que la antecubital (3,76 frente a 1,62; $p < 0,001$). Los futuros estudios que comparen ambas vías de inyección de salino deberían controlar el grado de opacificación auricular derecha.

Palabras clave: Ecocardiografía de contraste. Ultrasonografía intravascular. Foramen oval. Venas.

INTRODUCTION

Persistent patency of the foramen ovale into adulthood has clinical implications.¹ Echographic detection of patent foramen ovale (PFO) is based on evidence of the early passage of microbubbles to the left chambers of the heart or the systemic arteries after intravenous injection of a first-generation echo contrast, usually agitated saline solution.^{2,3} It has been shown that femoral injection increases the sensitivity of the technique, when compared to antecubital injection.^{4,5} This difference has been assumed to be due to the orientation of the right atrial-

inferior vena cava junction facing the fossa ovalis, with contribution of the Eustachian valve.²⁻⁵ However, improved right atrial opacification after contrast injection into a central vein has not been specifically investigated. This study compares the results of injections of agitated saline solution into the femoral vein and the antecubital vein on intracardiac echocardiography (ICE) of the atria.

METHODS

The study included patients scheduled for electrophysiological study (EPS) requiring transeptal puncture. All patients underwent transthoracic echocardiography (TTE) using second harmonic imaging and transesophageal echocardiography (TEE) in the 48 h before EPS, including a study with agitated saline for detection of patent foramen ovale (PFO).⁶ The agitated saline study by TTE and TEE consisted of a baseline injection and another with the Valsalva maneuver (VM),

Correspondence: Dr. D.R. Saura Espín.
Puerta de Orihuela, 3 bis; 7.º D. 30003 Murcia. España.
E-mail: danielsaura@secardiologia.es

Received October 25, 2006.
Accepted for publication March 1, 2007.

for which patients had been previously instructed. The release phase of the VM was made to coincide with the time point at which contrast clearly filled the right atrium. An intracardiac echocardiography (ICE) was also done during the EPS to assist with transseptal puncture.⁷ All patients received intravenous sedation with continuous propofol perfusion (effect-adjusted dose around 8 mg/kg/h). A radial imaging catheter with mechanical rotation was used for intracardiac echocardiography (Ultra ICE™ 9F/9MHz, Boston Scientific Corp; USA) and an intravascular ultrasound console (Galaxy²™ IVUS Imaging System, Boston Scientific Corp; USA). The catheter was advanced to the right atrium and positioned in the region of the fossa ovalis, and image gains were adjusted to obtain slight background noise. A right antecubital venous line was cannulated with an 18 G catheter, and the right femoral vein with a 4 Fr catheter. Using two 10-mL syringes connected to a three-way valve, contrast was obtained by brisk passage of 9.5 mL of normal saline and 0.5 mL of air between the 2 syringes. Ten mL of saline contrast were subsequently injected into the antecubital and femoral vein, ensuring that the contrast of the previous injection was not visible. In the ICE study, only 1 injection was performed per each route to simplify the procedure. The VM was carried out in each of these injections. The ICE images were recorded in DICOM and super-VHS format for subsequent interpretation. Two cardiologists with experience in contrast and intracardiac echocardiography scored by consensus the degree of enhancement in the right atrium from 0 to 4 (0=absence of echo contrast, 4=dense, homogeneous opacification of the right atrium). The images of contrast injections from the same patient were never shown consecutively and the observer was unaware of the injection site used for each image. The Wilcoxon *t* test was used to compare the degree of opacification.

Characteristics of Study Patients*

Patients	21
Mean age, years	49 (15)
Men	13 (62%)
Stroke	3 (14%)
Clinical arrhythmia	
Atrial fibrillation	19 (90%)
Atrial tachycardia	1 (5%)
Left atrial flutter	1 (5%)
Detection of PFO	
TTE	7 (33%)
TEE	3 (14%)
ICE	0 (0%)

*ICE indicates intracardiac echocardiography; PFO, patent foramen ovale; TEE, transesophageal echocardiography; TTE, transthoracic echocardiography.

RESULTS

The characteristics of the 21 patients included in the study are shown in Table. No patient had structural heart disease and no complications were caused by the study procedures. Contrast injection via the antecubital route achieved a medium degree of intensity of 1.62 (0.67), whereas the medium opacification achieved by femoral route was 3.76 (0.44). This difference was statistically significant ($P<.001$). The Figure shows the type of image obtained. Foramen ovale patency could not be demonstrated by intracardiac echocardiography in any patient, despite high-grade imaging and prolonged recording of images after the injection. Previously, PFO was detected in 14% of these patients by TEE and in 33% by TTE ($P=NS$), by early passage of bubbles to the left atrium.

DISCUSSION

Two studies^{4,5} have shown that contrast injection by the femoral vein has greater sensitivity for ultrasound detection of PFO than antecubital injection. This superiority has been attributed to the unique position of the right atrial-inferior vena cava junction, where flow is aimed toward the foramen ovale region.²⁻⁵ In these series, the degree of right atrial opacification obtained with each injection type was not specifically monitored. Good, dense contrast in the right atrium could improve PFO detection³ and would obtain a greater demonstrable degree of passage of bubbles into the left heart after a considerable increase of the right atrial pressure.

The present study shows that injection of the same volume of contrast into the femoral vein produces dense, homogeneous opacification of the right atrium, significantly greater than that obtained with injection into the antecubital vein. This fact could have acted as a confounding factor in studies comparing antecubital and femoral injections of agitated saline for the diagnosis of PFO.^{4,5} Future studies with contrast echocardiography should monitor the degree of right opacification obtained with each injection type.

Patent foramen ovale was not shown in any patient with the use of contrast ICE, even though images with excellent resolution of both atria and the fossa ovalis region were obtained and the patient was asked to perform the VM. There are no previous studies on PFO using contrast ICE; however, given the quality of the images, we doubt that the sensitivity of this ultrasound method is absolutely null, despite our results. All patients had previously performed the VM during TEE and TTE, and some had shown early evidence of shunting. The absence of bubble passage into the left atrium with ICE could be attributed to ineffective performance of the VM during ICE. This observation is consistent with the trend to a lower sensitivity of TEE compared with TTE using second harmonic imaging for PFO detection observed in our

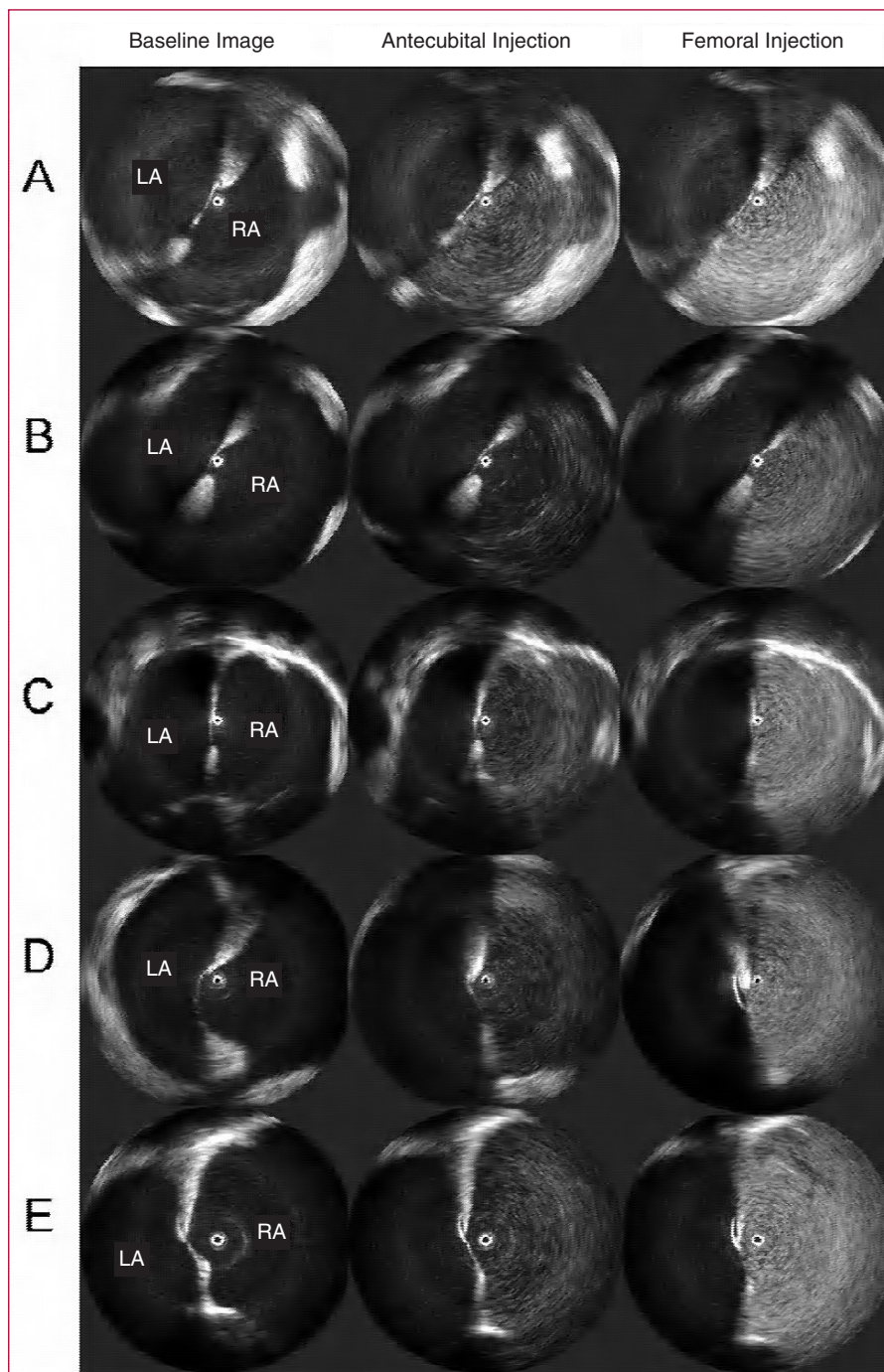


Figure. Intracardiac ultrasound images. Rows A-E: representative cases. First column: baseline image of intracardiac echocardiography. Second column: echo contrast of right atrium after antecubital injection of agitated saline. Third column: echo contrast of right atrium after femoral injection. Note that opacification is more intense after femoral versus antecubital injection. LA indicates left atrium; RA, right atrium.

study, and is consistent with findings in the literature.⁶ Although not an explicit part of the protocol, patients at our hospital were usually sedated with midazolam at the operator's discretion for TEE. In addition to the effect of sedation on the low effectiveness of VM, the possibility that patients with esophageal intubation or central venous lines perform the VM less vigorously should be considered.

Factors other than the injection site could have contributed to the differences observed between the administration routes. Quantitation of the degree of left atrial opacification was blinded for the source of each injection, although the echocardiography specialists were able to identify the outflow of contrast and infer the injection site. However, the differences obtained would outweigh the importance of the necessarily

inadequate blinding for the injection site. The femoral injection was done using the same volume of contrast as the antecubital injection, even though the gauge of the femoral catheter would have allowed higher flow. Studies that have previously compared the 2 injections did not control catheter size, and one of them used the femoral vein access for hemodynamic studies of the right side.^{4,5} Although the expected risk of complications is low, it was not considered ethical to cannulate the femoral vein with an 18 G catheter unless there was an additional clinical purpose. In order to precisely assess the importance of flow direction on the difference between the antecubital and the femoral vein injections of saline contrast for PFO detection, future studies should quantitatively measure opacification of the right atrium.

In conclusion, femoral vein injection of contrast leads to significantly greater density of right atrial opacification than antecubital injection. This should be taken into account in studies that compare antecubital and femoral vein injections of agitated saline for echocardiographic detection of PFO.

REFERENCES

1. Hara H, Virmani R, Ladich E, Mackey-Bojack S, Titus J, Reisman M, et al. Patent foramen ovale: current pathology, pathophysiology, and clinical status. *J Am Coll Cardiol.* 2005;46:1768-76.
2. Woods TD, Patel A. A critical review of patent foramen ovale detection using saline contrast echocardiography: when bubbles lie. *J Am Soc Echocardiogr.* 2006;19:215-22.
3. Attaran RR, Ata I, Kudithipudi V, Foster L, Sorrell VL. Protocol for optimal detection and exclusion of a patent foramen ovale using transthoracic echocardiography with agitated saline microbubbles. *Echocardiography.* 2006;23:616-22.
4. Gin KG, Huckell VF, Pollick C. Femoral vein delivery of contrast medium enhances transthoracic echocardiographic detection of patent foramen ovale. *J Am Coll Cardiol.* 1993;22:1994-2000.
5. Hamann GF, Schatzer-Klotz D, Frohlig G, Strittmatter M, Jost V, Berg G, et al. Femoral injection of echo contrast medium may increase the sensitivity of testing for a patent foramen ovale. *Neurology.* 1998;50:1423-8.
6. Daniels C, Weytjens C, Cosyns B, Schoors D, De SJ, Paelinck B, et al. Second harmonic transthoracic echocardiography: the new reference screening method for the detection of patent foramen ovale. *Eur J Echocardiogr.* 2004;5:449-52.
7. Villacastin J, Castellano NP, Moreno J, Álvarez L, Morales R, Rodríguez A. Resultados de la curva de aprendizaje de la punción transeptal guiada mediante ecografía intracardiaca. *Rev Esp Cardiol.* 2004;57:359-62.