

tendency to overtreat women at moderate or low CVR. The evidence thus indicates that women at very high or high CVR receive less effective treatment than men in the same risk categories.

Our study highlights the value of research into strategies aimed at increasing health care professionals' awareness of the need for gender equality in the approach to CVR, especially in relation to women in secondary prevention or at very high or high risk. This would also result in a more efficient use of lipid-lowering drugs.

FUNDING

Plan Nacional de Investigación Científica 2004–2007 (PI071218), Río Hortega (CM08/00141) contract from the Instituto de Salud Carlos III, Fellowship from the Plan Integral de Enfermedades Cardiovasculares de Extremadura, Fundesalud, Junta de Extremadura.

Francisco Javier Félix-Redondo,^{a,b} Luis Lozano-Mera,^{b,c} José María Mostaza,^d Pedro Saénz,^e Daniel Fernández-Berges,^{b,f} and Francisco Buitrago^{b,g,*}

^aCentro de Salud Villanueva Norte, Villanueva de la Serena, Badajoz, Spain

^bUnidad de Investigación GRIMEX, Programa de Investigación de Enfermedades Cardiovasculares (PERICLES), Badajoz, Spain

^cCentro de Salud Urbano I, Mérida, Badajoz, Spain

^dUnidad de Arteriosclerosis, Hospital Carlos III, Madrid, Spain

^eUnidad de Lípidos, Hospital de Mérida, Mérida, Badajoz, Spain

^fUnidad de Investigación, Área de Salud Don Benito-Villanueva de la Serena, Badajoz, Spain

^gCentro de Salud Universitario La Paz, Badajoz, Spain

*Corresponding author:

E-mail address: fbuitrago@gmail.com (F. Buitrago).

Available online 24 October 2015

REFERENCES

1. Reiner Ž, Catapano AL, de Backer G, Graham I, Taskinen MR, Wiklund O, et al. Guía de la ESC/EAS sobre el manejo de las dislipemias. Rev Esp Cardiol. 2011;64:1168.e1–e60.
2. Tabenkin H, Eaton CB, Roberts MB, Parker DR, McMurray JH, Borkan J. Differences in cardiovascular risk factor management in primary care by sex of physician and patient. Ann Fam Med. 2010;8:25–32.
3. Baena-Díez JM, Félix FJ, Grau M, Cabrera de León A, Sanz H, Leal M, et al. Tratamiento y control de los factores de riesgo según el riesgo de cardiopatía en la población española del estudio DARIOS. Rev Esp Cardiol. 2011;64:766–73.
4. Guallar-Castillón P, Gil-Montero M, León-Muñoz LM, Graciani A, Bayán-Bravo A, Taboada JM, et al. Magnitud y manejo de la hipercolesterolemia en la población adulta de España, 2008–2010, el estudio ENRICA. Rev Esp Cardiol. 2012;65:551–8.
5. Marrugat J, Solanas P, D'Agostino R, Sullivan L, Ordovas J, Cerdón F, et al. Estimación del riesgo coronario en España mediante la ecuación de Framingham calibrada. Rev Esp Cardiol. 2003;56:253–61.
6. Estudio de la prevalencia de los factores de riesgo cardiovascular en un Área Sanitaria de Badajoz. Estudio HERMEX. Metodología, resultados y conclusiones del Estudio Piloto [accessed August 4, 2015]. Available at: <http://www.grimex.org/prevencion-primaria-hermex/>

<http://dx.doi.org/10.1016/j.rec.2015.08.007>

Combined Percutaneous Mitral Valve Implantation and Paravalvular Leak Closure in a High-risk Patient With Severe Mitral Regurgitation



Reparación percutánea combinada de válvula mitral: cierre de fuga paravalvular e implante de prótesis transcáteter en paciente de alto riesgo con insuficiencia mitral grave

To the Editor,

The advantages of surgical mitral valve (MV) repair vs MV replacement have been extensively documented and it has become the preferred treatment option for patients with mitral regurgitation. However, recent studies have called into question the durability of MV repair, with a reoperation rate of up to 10% to 15% at 10 years of follow-up.¹ In cases of mitral regurgitation recurrence, reoperation often carries a high risk and a significant number of patients do not undergo surgery for this reason.

Isolated case reports have suggested the feasibility of transcatheter MV implantation in the presence of a ring annuloplasty.² In most of these cases, the transapical approach was used and a Melody[®] or Edwards SAPIEN percutaneous valve was implanted into the mitral ring.^{3–6}

We report the case of a young man with MV repair failure, in which a percutaneous complete repair of the failed surgery was performed, with transfemoral closure of mitral paravalvular leak and implantation of an Edwards SAPIEN XT valve in the mitral ring in the same procedure.

A 62-year-old man was admitted due to congestive heart failure. Ten years before, the patient underwent coronary artery bypass (left internal mammary to left anterior descending artery and saphenous vein graft to circumflex) with MV repair and implantation of a 30-mm CE Physio semirigid ring (Edwards Lifesciences Inc; Irvine, California, United States). On admission, a transesophageal echocardiogram showed severe mitral regurgitation due to an antero-septal para-ring leak, with a central intravalvular jet related to leaflet degeneration and moderate left ventricular dysfunction (ejection fraction 40%) with severe pulmonary hypertension. A coronary angiogram was performed ruling out significant coronary disease, with patent coronary grafts. The patient was rejected for a new surgical intervention (logistic EuroSCORE 21.49%, Society of Thoracic Surgeons score 10.23%) and transfemoral valve-in-ring implantation with para-ring leak closure was planned.

After transeptal puncture, an arteriovenous loop was established with a hydrophilic straight tip wire that had crossed the leak retrograde from the left ventricle, snared in the left atrium and exteriorized through the femoral vein. Subsequently, a left Amplatz catheter was advanced from the venous size into the left atrium, crossing the MV anterograde with a hydrophilic wire, which was captured in the descending aorta and externalized through the femoral artery, creating the second venoarterial loop. After balloon dilation of the septum with a 16-mm balloon, a 29 Edwards SAPIEN XT prosthesis mounted reversely on an 18-F Novaflex delivery catheter (Edwards Lifesciences) was implanted inside the mitral ring under rapid pacing, with slow and controlled balloon inflation (Figure 1). After the valve implant a 7-F sheath was advanced through the first arteriovenous loop and after analysis of the transesophageal echocardiography images, a 14/5 AMPLATZERTM vascular plug III was

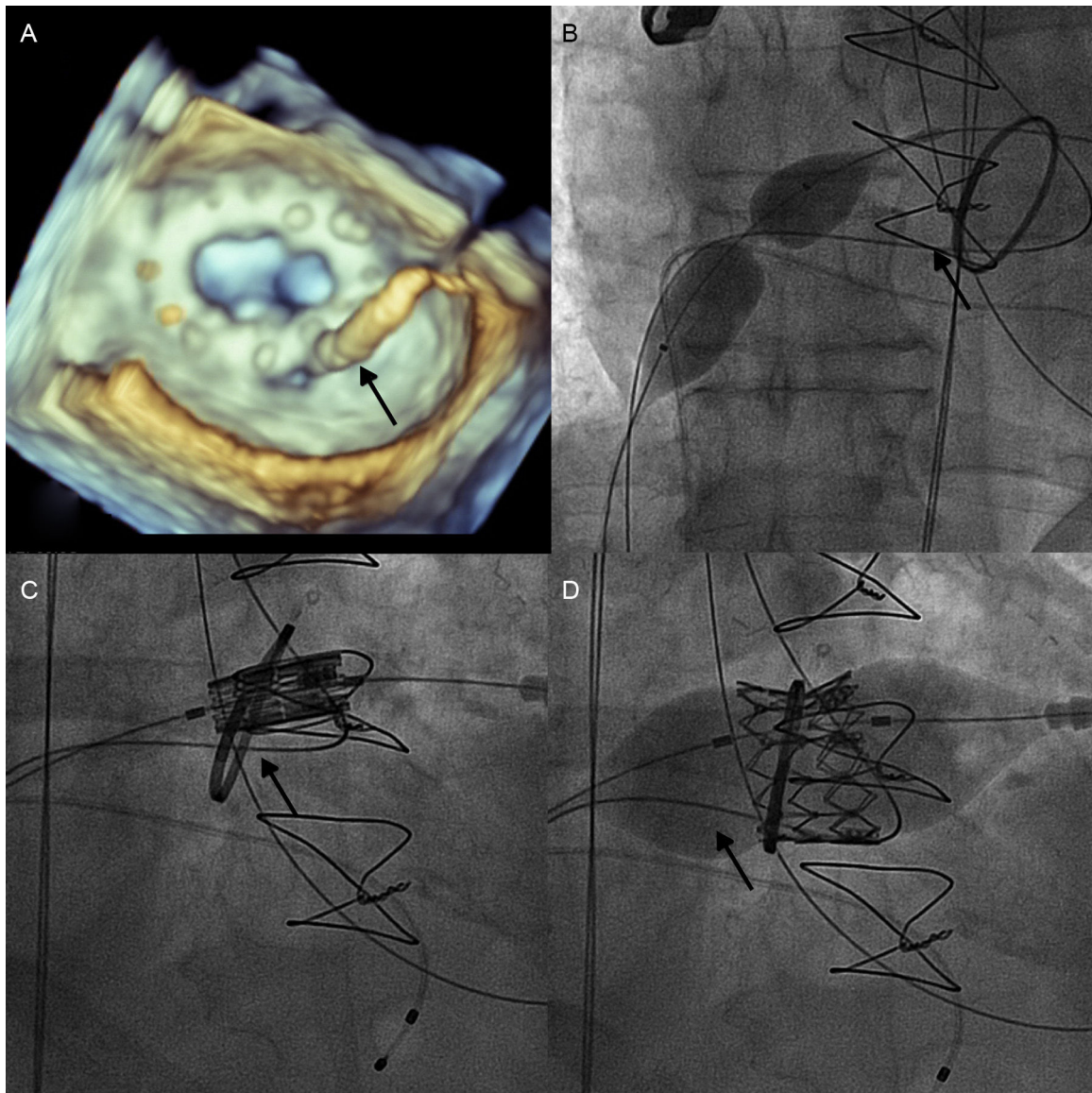


Figure 1. A: Three-dimensional transesophageal echocardiography of the wire (arrow) crossing the paravalvular leak. B: Balloon septostomy. C: Advance of the 29 Edwards SAPIEN XT valve into the mitral ring. D: Valve implantation, with 80% of the valve into the left ventricle.

implanted in the leak with a very good echocardiographic result and minimal residual mitral regurgitation (Figure 2).

The patient was discharged 3 days later and remains asymptomatic 6 months after the procedure.

Complete percutaneous treatment of a failed surgical repair with significant valvular and para-ring regurgitation can be performed in high-risk patients, with transfemoral closure of mitral para-ring leak and implantation of Edwards SAPIEN XT in the mitral ring during the same procedure.

The strategy of the intervention is essential to avoid potential complications, enabling the success of the procedure and improving the final result.

In this case, the 2 arteriovenous loops were performed at the beginning of the procedure, implanting the valve before the leak closure. This approach may have different advantages; the size and shape of the leak can be modified after the valve implantation, providing better apposition between the ring and the surrounding tissue, thus reducing the leak size and easing the para-ring leak

closure. In addition, the valve structure provides better anchor for the vascular plug that can be easily delivered, monitoring at the same time a potential interference of the device with the implanted valve.

The first cases of transcatheter valve implantation inside the mitral ring were performed with Melody valves,² but the use of the Edwards SAPIEN XT is now preferred. The limited size of the Melody[®] valve restricts the ring size suitable for implantation of this valve. Furthermore, the lower profile and flexing possibilities of the Edwards delivery facilitates valve deployment.

An additional problem for the valve-in-ring implantation is that the mitral rings have a more oval shape whereas the valve has a round shape. In this regard, the greater radial force of the Edwards system valve in addition to a slow inflation can benefit the adaptation of the ring to the valve shape, with better result.

Complete transfemoral repair of a degenerative surgical mitral bioprosthesis with significant paravalvular regurgitation can be

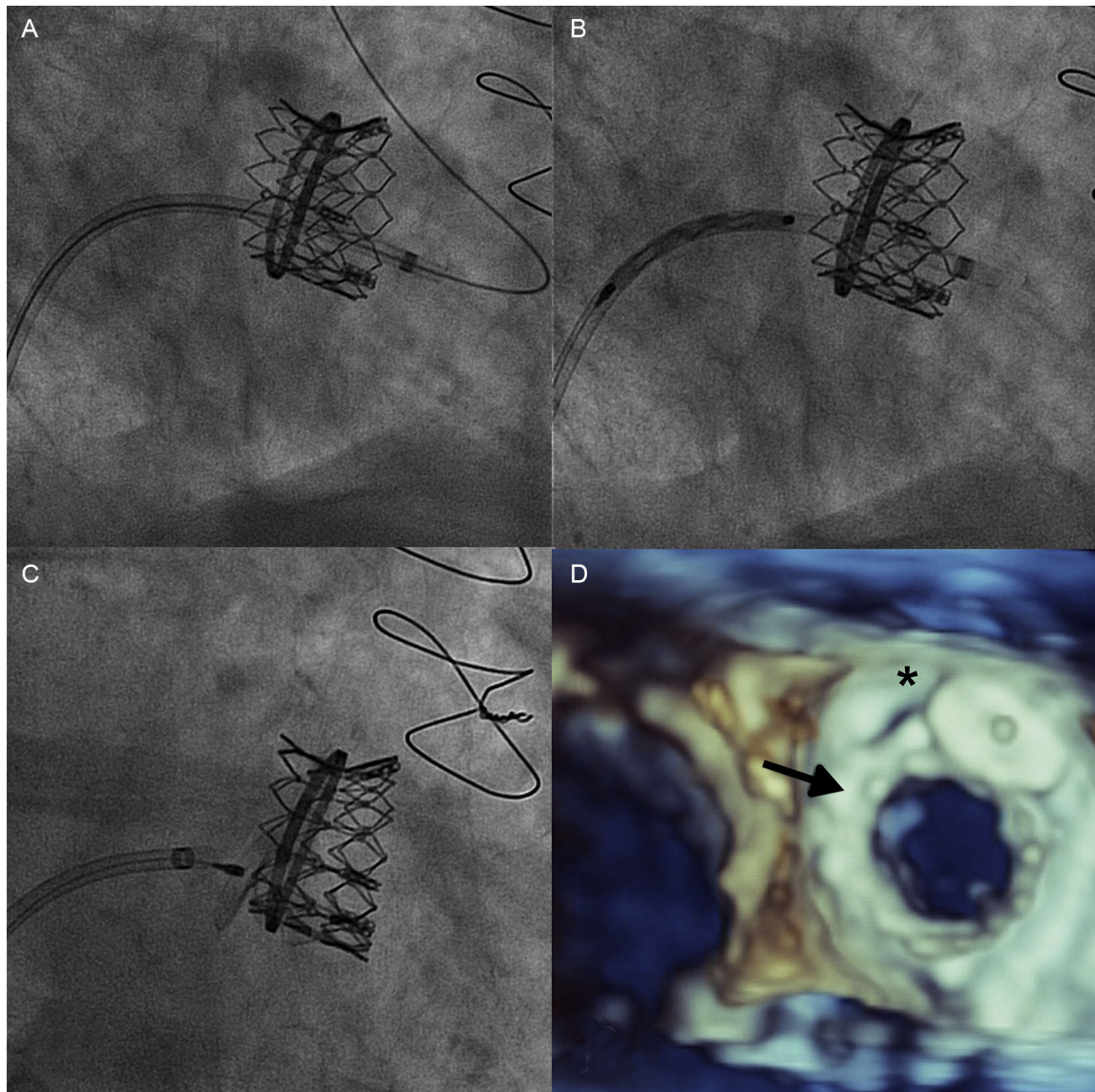


Figure 2. Para-ring leak closure. A: Sheath advance through the leak, into the left ventricle. B: Advance of the 14/5 Amplatzer vascular plug III device. C: Vascular plug implant. D: Final echocardiographic result (SAPIEN XT valve, arrow. Vascular plug, asterisk).

performed in high-risk patients with valve-in-ring implantation and para-ring leak repair during the same procedure.

Eulogio García,^a Leire Unzué,^{a,*} Carlos Almería,^b Ignacio Cruz,^c Luis Nombela,^b and Pilar Jiménez-Quevedo^b

^aServicio de Cardiología, Hospital Universitario Montepríncipe, Madrid, Spain

^bServicio de Cardiología, Hospital Clínico San Carlos, Madrid, Spain

^cServicio de Cardiología, Hospital Universitario de Salamanca, Salamanca, Spain

* Corresponding author:

E-mail address: leireunzue@yahoo.es (L. Unzué).

Available online 21 October 2015

REFERENCES

1. Shuhaiber J, Anderson RJ. Meta-analysis of clinical outcomes following surgical mitral valve repair or replacement. *Eur J Cardiothorac Surg.* 2007;31:267–75.
2. Kliger C, Angulo R, Maranan L, Kumar R, Jelnin V, Kronzon I, et al. Percutaneous complete repair of failed mitral valve prosthesis: simultaneous closure of mitral paravalvular leaks and transcatheter mitral valve implantation - single-centre experience. *EuroIntervention.* 2015;10:1336–45.
3. Shuto T, Kondo N, Dori Y, Koomalsingh KJ, Glatz AC, Rome JJ, et al. Percutaneous transvenous Melody valve-in-ring procedure for mitral valve replacement. *J Am Coll Cardiol.* 2011;58:2475–80.
4. de Weger A, Ewe SH, Delgado V, Bax JJ. First-in-man implantation of a transcatheter aortic valve in a mitral annuloplasty ring: novel treatment modality for failed mitral valve repair. *Eur J Cardiothorac Surg.* 2011;39:1054–6.
5. Casselman F, Martens S, de Bruyne B, Degrieck I. Reducing operative mortality in valvular reoperations: the 'valve in ring' procedure. *J Thorac Cardiovasc Surg.* 2011;141:1317–8.
6. Descoutures F, Himbert D, Maisano F, Casselman F, de Weger A, Bodea O, et al. Transcatheter valve-in-ring implantation after failure of surgical mitral repair. *Eur J Cardiothorac Surg.* 2013;44:e8–15.

<http://dx.doi.org/10.1016/j.rec.2015.08.008>