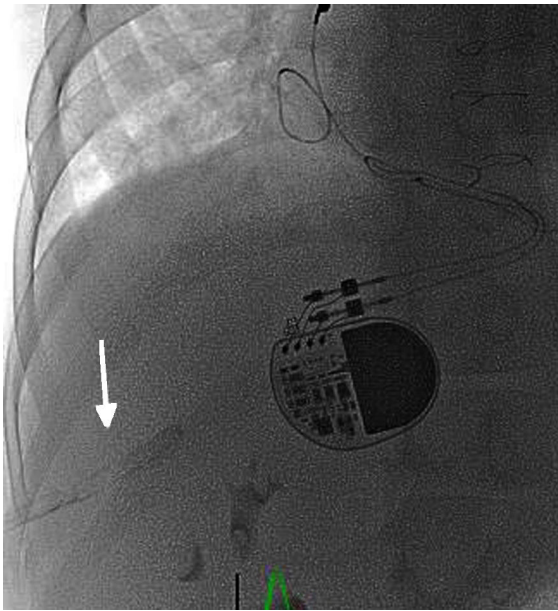

**Figure 2.** Posteroanterior fluoroscopy showing hemostatic material (arrow) closing the transhepatic tract.

Fallot, the main hemodynamic problem associated with functional deterioration is related to chronic pulmonary insufficiency.<sup>2</sup>

Because of the presence of congenital abnormalities in the systemic venous return, such as in patients with atrial isomerism who lack the inferior vena cava and in those with thrombosis of distinct central venous access sites due to their repeated use, it is necessary to turn to other less used vascular approaches. Transhepatic access has been used for patients with venous thrombosis for the rehabilitation of pulmonary branches of low-body weight pediatric patients<sup>3</sup> or with stenosis of the connection between the venae cavae and the right neoatrium after a Senning/Mustard intervention.<sup>4</sup> The most frequently described complications of this procedure are intra-abdominal bleeding and atrioventricular block.<sup>5</sup> The need for closure of the transhepatic tract to avoid bleeding is debated but it is recommended in patients receiving antiplatelet therapy when large-diameter sheaths are used, in younger patients, and in those with elevated right atrial pressure.<sup>6</sup> It should be closed using vascular plugs, coils, or hemostatic material. The increased incidence of atrioventricular block with this technique has been associated with posterior displacement of the guidewires and sheaths due to the approach, which would lead to a higher risk of conduction tissue dysfunction.<sup>5</sup>

## CONFLICTS OF INTEREST

J.L. Zunzunegui-Martínez is a proctor for Medtronic.

## SUPPLEMENTARY MATERIAL



Supplementary material associated with this article can be found in the online version available at <http://dx.doi.org/10.1016/j.rec.2017.02.045>

Félix Coserria-Sánchez,<sup>a,\*</sup> Álvaro Iglesias-López,<sup>b</sup> Manuel Villa Gil-Ortega,<sup>c</sup> Antonio Moruno-Tirado,<sup>a</sup> Francisco García-Angleu,<sup>a</sup> and José L. Zunzunegui-Martínez<sup>d</sup>

<sup>a</sup>Sección de Cardiología Pediátrica y Hemodinámica Infantil, Hospital Universitario Virgen del Rocío, Sevilla, Spain

<sup>b</sup>Servicio de Radiología Vasculare e Intervencionista, Hospital Universitario Virgen del Rocío, Sevilla, Spain

<sup>c</sup>Sección de Hemodinámica, Servicio de Cardiología, Hospital Universitario Virgen del Rocío, Sevilla, Spain

<sup>d</sup>Sección de Hemodinámica Pediátrica, Hospital Universitario Gregorio Marañón, Madrid, Spain

\*Corresponding author:

E-mail address: [felixcos@yahoo.es](mailto:felixcos@yahoo.es) (F. Coserria-Sánchez).

Available online 19 May 2017

## REFERENCES

- Girona J, Betrian P, Marti G. Implantación percutánea de válvula pulmonar. *Rev Esp Cardiol.* 2009;62:1068–1081.
- Subirana MT, Baron-Esquivias G, Manito N, et al. Actualización 2013 en cardiopatías congénitas, cardiología clínica e insuficiencia cardiaca y trasplante. *Rev Esp Cardiol.* 2014;67:211–217.
- Ebeid MR. Transhepatic approach for rehabilitation of stenosed pulmonary arteries. *Ann Pediatr Cardiol.* 2010;3:25–30.
- Del Val D, Alvarez M, Sanchez J, Fernandez L, Garrido-Lestache E, Del Cerro MJ. Recanalización percutánea de obstrucción completa de vena cava inferior en TCGA reparada con técnica de Mustard. *Rev Esp Cardiol.* 2016;69:1103–1115.
- Qureshi AM, Prieto LR, Bradley-Skelton S, Latson LA. Complications related to transhepatic venous access in the catheterization laboratory—a single center 12-year experience of 124 procedures. *Catheter Cardiovasc Interv.* 2014;84:94–100.
- Ebeid MR. Transhepatic vascular access for diagnostic and interventional procedures: techniques, outcome, and complications. *Catheter Cardiovasc Interv.* 2007;69:594–606.

<http://dx.doi.org/10.1016/j.rec.2017.02.045>  
1885-5857/

© 2017 Sociedad Española de Cardiología. Published by Elsevier España, S.L.U. All rights reserved.

## Colonoscopy and Endocarditis: A Compromised Relationship



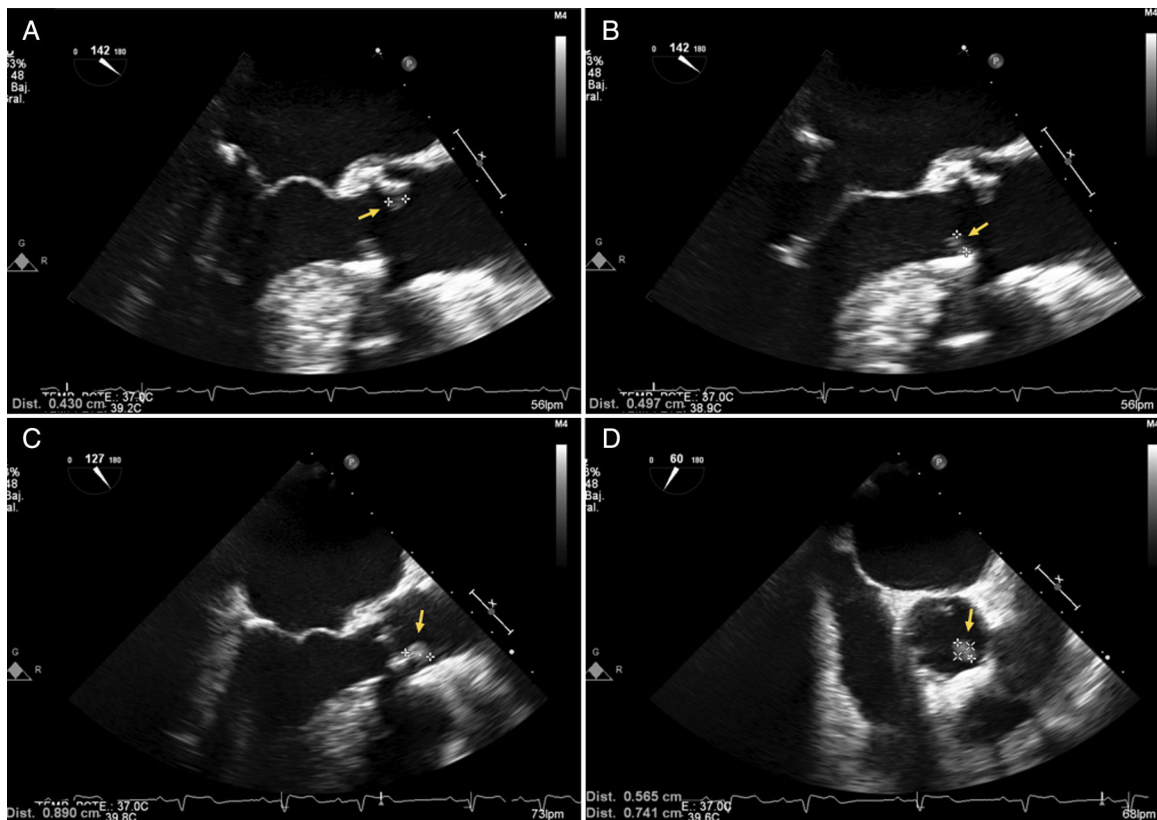### Colonoscopia y endocarditis: una relación comprometida

#### To the Editor,

We recently treated a patient with infective endocarditis (IE), and there was some controversy about the indication and risk of performing a colonoscopy examination.

An 82-year-old man with a history of hypertension and a biological prosthetic aortic valve implanted 4 years previously was seen for a 2-day history of fever (39 °C) with no focal infectious

source. He had not undergone dental treatment recently. On physical examination, several teeth were found to be in poor condition and a systolic murmur was detected at the left sternal border. There was no atrioventricular block on electrocardiography, and the analyses showed mild anemia (12.7 g/dL). Chest radiographs were normal. The initial transesophageal echocardiography (TEE) study showed no relevant abnormalities. Penicillin-susceptible *Streptococcus agalactiae* isolates were recovered from blood culture of all 4 vials obtained. A new TEE performed on the eighth day after hospitalization depicted 2 vegetations, 3 and 8 mm in size, on the prosthetic aortic valve (Figure 1). After the first TEE, <sup>18</sup>F-FDG positron emission tomography combined with computed tomography (PET/CT) had shown mild homogeneous



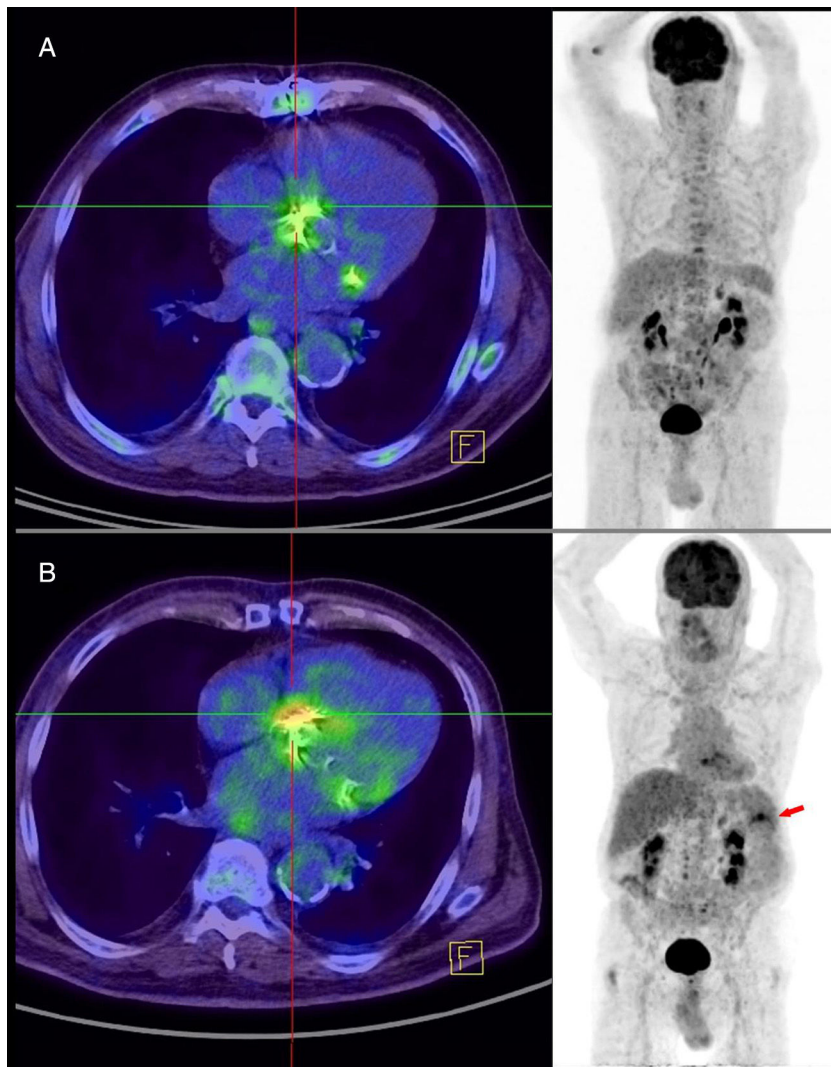
**Figure 1.** A and B, Transesophageal echocardiograms depict 2 mobile images (arrows) on the ventricular aspect of the aortic valve, corresponding to vegetations. C and D, The follow-up examination shows an increase in size (arrows) and an absence of periprosthetic complications.

uptake that did not suggest IE (Figure 2), although the patient already fulfilled some of the IE criteria (1 major and 3 minor).

Ceftriaxone 2 g/24 h was prescribed for 6 weeks and gentamicin 180 mg/24 h for the first 2 weeks, both given intravenously. Oral amoxicillin 1 g/6 h was then given for 2 additional weeks to treat left facet joint arthritis at L3-L4. Colonoscopy was performed in the fifth week of ceftriaxone treatment, and a 2-mm colon polyp was resected (tubular adenoma). The patient showed fever at 12 hours following this procedure. Four days after completion of antibiotic treatment, new blood cultures were obtained and *Enterococcus faecium* was isolated from the 4 vials. The patient had experienced low-grade fever over the past 7 days. The physical examination findings were unremarkable. Laboratory analyses showed worsening of the anemia (hemoglobin, 10.6 g/dL) and a C-reactive protein increase of 106 mg/dL (0.1-10 mg/dL). There were no signs indicative of IE on TEE examination. PET/CT depicted intense, irregular uptake at the prosthetic aortic valve, highly suspicious of IE (Figure 2) and a hypometabolic splenic lesion with peripheral uptake, approximately 6 × 4 cm in size, indicating a septic embolism. As the microorganism was resistant to ampicillin and gentamicin, the patient was treated with daptomycin 700 mg/24 h and fosfomycin 2 g/6 h for 6 weeks. The patient's clinical course was favorable and follow-up blood cultures were sterile.

This case prompted a 2-fold reflection: first, on how intensive the search should be for a possible infectious source in suspected IE, and second, on whether IE prevention measures should be taken in patients undergoing colonoscopy. Although European guidelines recommend colonoscopy only in cases of IE due to *Streptococcus gallolyticus*,<sup>1</sup> some authors believe a more intense

search for the probable infectious source (including colonoscopy) is advisable in patients older than 50 years.<sup>2</sup> Considering our patient's age and the possible intestinal origin of the infection (*S. agalactiae*), we decided to carry out colonoscopy while completing the antibiotic therapy. The scant relationship between *S. agalactiae* IE and the risk of colon cancer reported in the literature could justify omission of colonoscopy. Of particular note in the case reported was the development of a second IE episode due to a different microorganism (*E. faecium*). The prolonged ceftriaxone administration may have enhanced colonic proliferation of *E. faecium*, and colonoscopy may have led to an episode of bloodstream infection. Nonetheless, a recent review<sup>3</sup> found only 25 cases of IE attributable to endoscopic procedures, which supports the current recommendation to refrain from prophylactic antibiotic administration in patients undergoing such procedures.<sup>1</sup> The microorganisms most commonly implicated in these cases are enterococci and *viridans* streptococci.<sup>4</sup> To our knowledge, this is the first case of enterococcal IE occurring in a patient who underwent colonoscopy while receiving IE treatment. The bacterial strain causing the second episode was resistant to amoxicillin (the recommended antibiotic in the former indication). Of note, recent changes in antibiotic prophylaxis guidelines in western countries have led to substantial reductions in the number of patients for whom prophylaxis is recommended. In parallel, it has been reported that the incidence of IE may be increasing significantly since the introduction of these new recommendations.<sup>5</sup> Based on all of the above considerations, we believe that although the risk of IE is low in patients undergoing colonoscopy, prophylaxis may be justified in certain subgroups at a high risk.



**Figure 2.**  $^{18}\text{F}$ -FDG positron emission tomography. A, Uptake indicative of endocarditis is much more intense than during the first episode of endocarditis. B, At the second hospitalization, uptake indicative of endocarditis and an image of septic splenic embolism are observed.

Antonio Ramos-Martínez,<sup>a,\*</sup> Marta Cobo,<sup>b</sup> Alejandra Restrepo,<sup>b</sup> Jorge Mucientes,<sup>c</sup> Beatriz Orden Martínez,<sup>d</sup> and Begoña Rodríguez-Alfonso<sup>c</sup>

<sup>a</sup>Unidad de Enfermedades Infecciosas, Medicina Interna, Hospital Universitario Puerta de Hierro, Universidad Autónoma de Madrid, Majadahonda, Madrid, Spain

<sup>b</sup>Servicio de Cardiología, Hospital Universitario Puerta de Hierro, Majadahonda, Madrid, Spain

<sup>c</sup>Servicio de Medicina Nuclear, Hospital Universitario Puerta de Hierro, Majadahonda, Madrid, Spain

<sup>d</sup>Servicio de Microbiología, Hospital Universitario Puerta de Hierro, Madrid, Majadahonda, Spain

\* Corresponding author:

E-mail address: [aramos220@gmail.com](mailto:aramos220@gmail.com) (A. Ramos-Martínez).

Available online 8 August 2017

## REFERENCES

- Habib G, Lancellotti P, Antunes MJ, et al. 2015 ESC Guidelines for the management of infective endocarditis: The Task Force for the Management of Infective Endocarditis of the European Society of Cardiology (ESC). Endorsed by: European Association for Cardio-Thoracic Surgery (EACTS), the European Association of Nuclear Medicine (EANM). *Eur Heart J*. 2015;36:3075–3112.
- Delahaye F, M'Hammedi A, Guerpillon B, et al. Systematic search for present and potential portals of entry for infective endocarditis. *J Am Coll Cardiol*. 2016;67:151–158.
- Khashab MA, Chithadi KV, Acosta RD, et al. Antibiotic prophylaxis for GI endoscopy. *Gastrointest Endosc*. 2015;81:81–89.
- Norfleet RG. Infectious endocarditis after fiberoptic sigmoidoscopy. With a literature review. *J Clin Gastroenterol*. 1991;13:448–451.
- Dayer MJ, Jones S, Prendergast B, Baddour LM, Lockhart PB, Thornhill MH. Incidence of infective endocarditis in England, 2000–13: a secular trend, interrupted time-series analysis. *Lancet*. 2015;385:1219–1228.

<http://dx.doi.org/10.1016/j.rec.2017.07.007>  
1885-5857/

© 2017 Sociedad Española de Cardiología. Published by Elsevier España, S.L.U. All rights reserved.