

Collateral Aneurysms in Aortic Coarctation. A Contraindication for Percutaneous Intervention? Response



Aneurismas de la circulación colateral en la coartación aórtica, ¿son una contraindicación para el tratamiento percutáneo? Respuesta

To the Editor,

We read with interest the Letter to the Editor by Díez-Delhoyo et al. regarding 1 of the patients who died from massive hematemesis, described in our article on percutaneous stent placement to treat coarctation of the aorta due to atresia.¹ We would like to make a few points with regard to this case.

This patient received a late diagnosis of coarctation of the aorta with highly developed collateral circulation and an intercostal aneurysm distal to the area of atresia. The case was discussed in a clinical session and a percutaneous approach with selected due to the extremely high surgical risk in these patients, with potentially serious complications.²

In this patient, the aneurysm was previously under low pressure, given that it was distal to the area of coarctation. In such cases, after the obstruction is resolved, the pressure increases and, unless correct isolation is achieved, there is a higher risk of rupture, as occurred in our patient. Autopsy revealed that the stent

had lost its cover, which remained in the delivery sheath due to friction (Figure).

Our group has begun to use a new all-in-one system (Nudel delivery system, Numed) with success in several patients. This system is similar to that used with the Melody pulmonary valve, which increases safety during implantation because it prevents both stent migration and loss of the expanded polytetrafluoroethylene (ePTFE) cover.

On the basis of our experience and a literature review, we conclude that, in this type of coarctation of the aorta with extensive collateral circulation and intercostal aneurysms, the percutaneous approach is the treatment of choice to ensure complete isolation of aneurysms through coil embolization or Amplatzer devices^{2,3} or the use of covered stents.³ Consequently, preprocedural imaging study with computed tomography or magnetic resonance is essential for an adequate approach in these cases.^{2,3}

Luis Fernández González,* Roberto Blanco Mata, Koldobika García San Román, and Juan Alcibar Villa

Sección de Hemodinámica y Cardiología Intervencionista, Hospital Universitario de Cruces, Baracaldo, Vizcaya, Spain

*Corresponding author:

E-mail address: Luisfg82@hotmail.com (L. Fernández González).

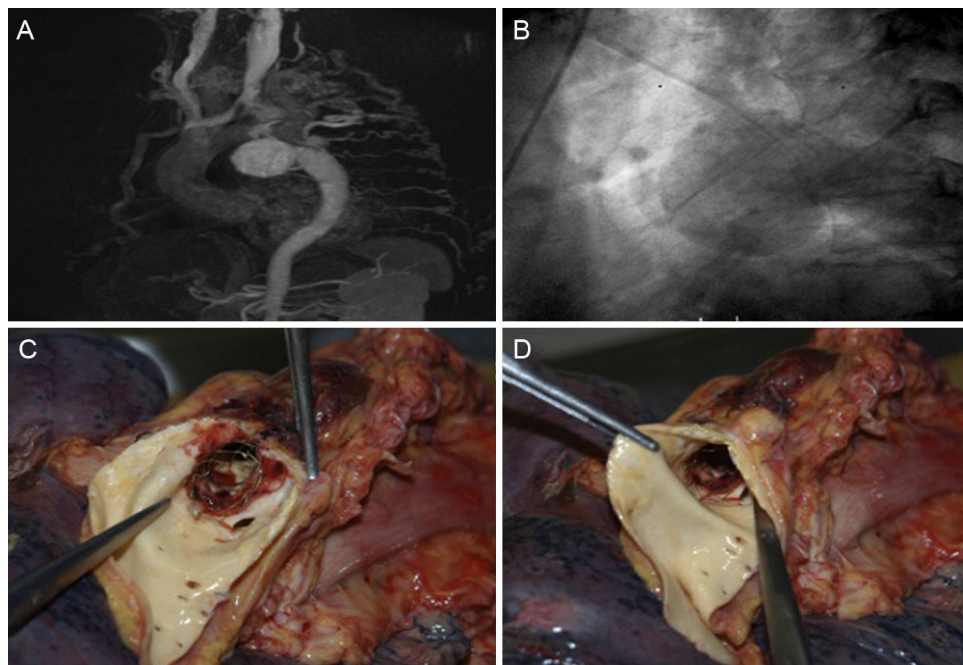


Figura. A: magnetic resonance image showing extensive collateral circulation, contrast enhancement of the descending aorta, and a giant intercostal aneurysm. B: late phases of the aortic angiogram show extensive collateral circulation to the descending aorta and a giant intercostal aneurysm. C and D: autopsy image showing loss of the stent cover.

REFERENCES

1. Fernández González L, García San Román K, Blanco Mata R, et al. Tratamiento percutáneo con *stent* de la coartación aórtica de aorta en el adulto. *Rev Esp Cardiol*. 2016;69:1109–1111.
2. Tapping CR, Ettles DF. Endovascular management of bilateral superior intercostal artery aneurysms following late repair of coarctation of aorta. *Thorac Cardiovasc Surg*. 2011;59:311–313.
3. Batlivala SP, Rome JJ. Concomitant percutaneous treatment of aortic coarctation and associated intercostal aneurysms: pre-procedural recognition is key. *Cardiol Young*. 2016;26:390–395.

SEE RELATED ARTICLE:
<http://dx.doi.org/10.1016/j.rec.2016.09.035>

<http://dx.doi.org/10.1016/j.rec.2016.12.017>
 1885-5857/

© 2016 Sociedad Española de Cardiología. Published by Elsevier España, S.L.U. All rights reserved.

Evaluation of HAS-BLED and ORBIT Bleeding Risk Scores in Nonvalvular Atrial Fibrillation Patients Receiving Oral Anticoagulants



Evaluación de los esquemas de riesgo hemorrágico HAS-BLED y ORBIT en pacientes con fibrilación auricular no valvular tratados con anticoagulación oral

To the Editor,

We read with interest the letter by Riziq-Yousef Abumuaileq et al.¹ on bleeding risk scores in atrial fibrillation (AF). The authors analyzed the differences in prediction of major and intracranial bleeding between the ORBIT, HAS-BLED, and ATRIA risk scores. They concluded that the ORBIT score works as well as the HAS-BLED score, both in the general population and in patients with labile international normalized ratio (INR). After reading the letter, we make the following points.

The European guidelines for AF have recently been published.² These recommend the use of bleeding risk scores for patients receiving oral anticoagulation (class of recommendation IIa, level B), regardless of the ischemic stroke risk calculated with the CHA₂DS₂-VASc score. Although none of the bleeding risk scores were superior to the others, of note is the importance in clinical practice of controlling 4 modifiable risk factors: hypertension, INR lability, drugs that may induce bleeding, and excess alcohol intake. All these modifiable factors are included in the HAS-BLED score. The ORBIT score arose as a tool for evaluating bleeding risk in patients receiving any type of anticoagulant treatment.³ Assessment of INR lability is therefore not assessed given that this variable is complex and not useful in patients on direct anticoagulants, which are at least as effective as vitamin K antagonists (VKA) in preventing embolic events and in reducing intracranial bleeding. However, their use in Spain is limited (11.2% according to the PREFER-AF registry). The effectiveness of VKA therapy depends on the quality of anticoagulation estimated by time in therapeutic range (TTR), which should be as high as possible.² We therefore believe that, to make an appropriate comparison between risk scores, the quality of anticoagulation should be assessed with INR, because INR control is used in the HAS-BLED risk score. The lack of sufficient data on INR control before inclusion may have had an impact on the results of Riziq-Yousef Abumuaileq et al.¹

Our group has analyzed the differences between the HAS-BLED and ORBIT risk scores for predicting mortality and major bleeding in 2 populations: patients with chronic nonvalvular AF (NVAF) in the FANTASIIA Spanish registry and patients with NVAF who underwent electrical cardioversion.⁴ In total, 406 patients with NVAF (median TTR, 60% [range, 50%–68%], 39.2% with TTR < 60%) and 1276 patients in the FANTASIIA registry (mean TTR, 60.9% ± 24.4%, 54% with TTR < 65%) were analyzed. In patients who underwent electrical cardioversion, no significant differences

between the HAS-BLED and ORBIT risk scores were observed in prediction of major bleeding and mortality. Likewise, in patients in the FANTASIIA registry, no significant differences were observed in prediction of bleeding and mortality. These findings are consistent with those published by Senoo and Lip⁵ in the AMADEUS study population.

We therefore believe that the ORBIT score does not represent an improvement over the HAS-BLED score for predicting bleeding and does not help in clinical management. Modifiable factors are therefore not included in this score. A high bleeding risk score is not a contraindication for anticoagulation, but it does serve as a warning to modify harmful factors in our patients receiving anticoagulation therapy with a dynamic score such as the HAS-BLED score.

In patients with NVAF, simplicity is essential to prevent events:

1. Calculate the ischemic stroke risk with the CHA₂DS₂-VASc score to exclude patients who do not benefit from anticoagulation.
2. Calculate the HAS-BLED bleeding risk score to identify modifiable bleeding risk factors.
3. Use the SAME-TT₂R₂ score to identify patients with poor INR control and to determine which patients are candidates for treatment with VKA (SAME-TT₂R₂ 0–1) or with direct anticoagulants (SAME-TT₂R₂ ≥ 2).

CONFLICTS OF INTEREST

The FANTASIIA registry is supported by an unconditional grant from Pfizer/Bristol-Myers-Squibb and by subsidies from the *Instituto de Salud Carlos III* (ISCIII) (Madrid)-FEDER (RD12/0042/0068, RD12/0042/0010, RD12/0042/0069, and RD12/0042/0063).

The authors are funded by RD12/0042/0049 (RETICS) of the ISCIII and PI13/00513/FEDER of the ISCIII.

María Asunción Esteve-Pastor,^a Amaya García-Fernández,^b Vanessa Roldán,^c and Francisco Marín^{a,*}

^aServicio de Cardiología, Hospital Clínico Universitario Virgen de la Arrixaca, IMIB-Arrixaca, El Palmar, Murcia, Spain

^bServicio de Cardiología, Hospital General Universitario de Alicante, Instituto de Investigación Sanitaria y Biomédica ISABIAL-FISABIO, Alicante, Spain

^cServicio de Hematología, Hospital Universitario Morales Meseguer, Murcia, Spain

*Corresponding author:

E-mail address: fcomarino@hotmail.com (F. Marín).

Available online 27 December 2016