

Catheter-Related Central Venous Thrombosis in the Course of an Uncomplicated Acute Myocardial Infarction: Diagnostic Usefulness of Echocardiography

Arturo Zabalegui Pérez, José M. Ayuela Azcárate, Germán Pérez Ojeda, Purificación Busto Sanz, Amparo García González and José A. Fernández Ratero

Servicio de Medicina Intensiva y Sección de Cardiología. Hospital General Yagüe. Burgos.

In certain cases such as cancer patients or patients with coagulopathies, the venous thrombosis is a frequent complication that is associated with the implantation of central venous catheters. However, it is uncommon in other contexts, such as acute myocardial infarction without complications in its fifth day of evolution, after being treated with platelet inhibitors in addition to the initial anticoagulant and fibrinolytic therapy. We present a case of thrombosis in the superior vena cava and in the right atrium related to a peripherally inserted central catheter in this clinical context. The utility of transesophageal and transthoracic echocardiography in the differential diagnosis with other cardiac structures and in the evolutionary control is commented. Likewise, potential complications and the treatment of this pathology are discussed.

Key words: *Catheters. Thrombosis. Echocardiography.*

Full English text available at: www.revespcardiol.org

Trombosis venosa central asociada a catéter en el curso de un infarto agudo de miocardio no complicado: utilidad diagnóstica de la ecocardiografía

En ciertos casos, como en los enfermos oncológicos o con coagulopatías, la trombosis venosa es una complicación frecuente asociada a la inserción de catéteres centrales venosos. Sin embargo, es rara en otros contextos, como el de un infarto agudo de miocardio no complicado en su quinto día de evolución, tratado con terapia antiagregante además del tratamiento anticoagulante y fibrinolítico inicial. Se presenta un caso de trombosis de vena cava superior y aurícula derecha, secundario a un intracatéter periférico de localización central en dicho contexto clínico. Se comenta el papel de la ecocardiografía transtorácica y transesofágica en el diagnóstico diferencial con otras estructuras cardíacas y en el seguimiento evolutivo. Asimismo, se discuten las potenciales complicaciones y el tratamiento de esta afección.

Palabras clave: *Catéteres. Trombosis. Ecocardiografía.*

INTRODUCTION

Centrally-located peripheral venous catheters are used for the administration of various treatments and for hemodynamic monitoring.¹⁻⁴ In patients with acute myocardial infarction (AMI), implantation of a central catheter via the cephalic or basilic vein has the advantage of rapid pharmacological delivery without the known inherent risks of central access (particularly bleeding secondary to AMI treatment). Nevertheless, given their known thrombogenic action,⁵ both types of catheter (central or centrally-located peripheral) carry

the risk of thrombosis in the area of the catheter (jugular, subclavian, brachiocephalic, cava, or right atrial vein). Autopsy and radiological studies have shown a high (35% to 67%) incidence of thrombosis in catheterized central veins (TCCV).^{4,5} However, the diagnosis can be missed because the thrombus may disappear upon removal of the catheter.⁶

This complication occurs more frequently in patients with cancer,⁷ critically-ill patients,⁶ heparin-induced thrombocytopenia and thrombosis (HITT), coagulopathies, nephrotic syndrome, immunological diseases (Behcet, disseminated lupus erythematosus, Churg-Strauss, Horton),⁸ pediatric patients,⁹⁻¹¹ or in the absence of antithrombotic prophylaxis. It is extremely rare in AMI patients who have received antiagregate, anticoagulant, and fibrinolytic therapy.

We present a clinical case of thrombosis of the superior vena cava extending into the right atrium and associated with a peripheral central indwelling catheter,

Correspondencia: Dr. A. Zabalegui Pérez.
Servicio de Medicina Intensiva. Hospital General Yagüe.
Avda. del Cid, 96. 09005 Burgos. España
E-mail: azaba@hgy.es

Recibido el 17 de mayo de 2001.
Aceptado para su publicación el 29 de agosto de 2001.

during the course of an acute myocardial infarction (AMI). The diagnosis of thrombosis of the catheterized central veins (TCCV) was made by echocardiography.

CLINICAL CASE

A 55-year-old patient, a smoker, was admitted to our hospital with acute ischemic heart disease. After posterior-inferior AMI was diagnosed, platelet aggregation inhibitor treatment was initiated (through an indwelling Drum Cartridge® catheter introduced into the right basilic vein up to the right subclavian) with acetylsalicylic, fibrinolytic with alteplase (Actilise®), 100 mg in 90 minutes, and anticoagulant with intravenous sodium heparin (Heparin-Leo®) in perfusion for 72 hours. The patient's clinical course was uneventful, except for the appearance of discrete signs of thrombophlebitis in the right upper extremity 5 days after admission; the catheter was removed for this reason.

Routine transthoracic echocardiography (TTE) performed on the fifth day revealed a linear image in the right atrium. As a result, transesophageal echocardiography (TEE) was performed, revealing thrombosis of the superior vena cava extending into the right atrium, shaped like the vein in which it had formed and without an anchor point, as the catheter had been removed (Figure 1). Following the diagnosis (also confirmed by helicoid thoracic computerized tomography) of thrombosis of the superior cava and the right atrium, anticoagulant intravenous heparin (Heparin-Leo®) treatment was reinitiated via continuous perfusion in order to maintain a partially activated thromboplastin time of between 50 and 70s. Control of thrombus development was confirmed by new TEE 4 days after the diagnosis of TCCV, and its resolution was revealed by TEE on the 7th day. After initiation of oral anticoagulation treatment with acenocumarol

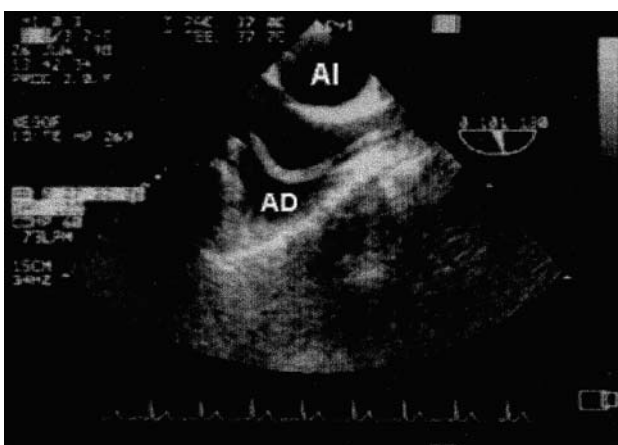


Fig. 1. Superior transesophageal plane: tortuous high density image of thrombus which extends into the right atrium (RA) and originating in the superior vena cava. LA indicates left atrium.

(Sintrom® INR between 2 and 3) the patient was discharged on day 13, with anticoagulation treatment being maintained for 1 month.

DISCUSSION

In spite of the frequent association between central venous catheterization and TCCV (35% to 67% of cases)^{4,6}, it is rare in the clinical case described, with diagnosis on the 5th day of a fibrinolized, anticoagulation, and antiaggregated AMI. Although heparin therapy had been suspended 24 hours before the diagnosis of TCCV, and therefore, this drug was no longer active (nor was fibrinolytic treatment) these therapies impeded the initiation of thrombosis while they were active. Also, in this patient there were no risk factors such as neoplasia, HITT (since a recent platelet count was normal), or thrombotic considerations. Nevertheless, during the acute phase of the AMI, anticoagulant treatment was necessary, and without specialized laboratory tests being available, it was not possible to completely discard a diagnosis of primary hypercoagulability (antithrombin III deficiency, hypodisfibrinogenemia, protein C resistance, prothrombin 20210 A, etc), or secondary (hyperhomocystinemia, antiphospholipid antibodies, etc). There was no relevant personal or family history.

It is not known whether smoking or hyperlipidemia (which was discovered on admission) could be related to venous thrombosis; nevertheless, the presence of an endothelial vascular lesion indicates they could be contributing factors, especially in association with other procoagulant factors such as catheter contact with the vascular wall.

The clinical picture of this illness can be very variable, ranging from asymptomatic to potentially life-threatening complications such as sepsis¹² and pulmonary thromboembolism (PTE). The incidence of PTE (the most characteristic illness secondary to TCCV) is estimated at 20%⁶. In our case, we only observed slight signs of local swelling in the right arm.

Early diagnosis is fundamental. In our patient, despite the thrombophlebitis, there was no suspicion and discovery was made on routine TEE on the 5th day, and confirmed by subsequent TEE.

Various studies have established the superiority of TEE over TTE for imaging localized masses in vena cava or right atrium.^{1,2,4,6,10,13} TEE can provide an adequate differential diagnosis in the early stage (before complications occur), evaluate the morphology and extent of the thrombosis, control the efficacy and duration of treatment and rule out complications. TEE allows establishment of the differential diagnosis with an Eustachio valve, Tebesio valve, Chiari web, crista terminalis, and pectineal muscles of the right atrium. With regard to morphology, TEE can discriminate between the 2 types of TCCV: thrombus around the cat-

heter or thrombus of the wall with complete or partial occlusion of the venous vessel; in our patient it took the form of the original catheter, without an anchor point (since the conduit had been removed), characteristics that indicate a high embolization risk¹⁴.

Other diagnostic techniques, such as venography, thoracic helicoidal computerized tomography (also used in this case), scintillography with indium 111, etc., may be helpful for differential diagnosis and for calculating thrombus age.

The best therapy is prevention or early treatment (through early diagnosis) to reduce mortality and morbidity secondary to potential complications.

In spite of the known efficacy of non-divided heparin as an antithrombotic, it can cause secondary effects such as heparin-induced thrombocytopenia/thrombosis (HITT) (with a high risk of thrombosis)^{15,16} and hemorrhage; in low molecular weight heparin HITT has not been described, and it could have greater antithrombotic power (greater inhibition of coagulation X factor) than an anticoagulant (less inhibition of coagulation II factor), with its corresponding lesser risk of bleeding.¹⁷ Nevertheless, any of these prophylactic therapies is effective. Low doses of nitroglycerine in continuous perfusion, based on the liberation of nitric oxide and its vasodilator and antithrombotic effects, has also been proposed as preventative therapy; nevertheless its usefulness has not been proven.¹¹

Initial action in serious cases should be supportive therapy and anticoagulant and fibrinolytic treatment.⁴ Cardiac surgery should be reserved for those serious cases where fibrinolytic treatment is contraindicated.⁴

Currently, although definitive treatment is catheter removal, there is not enough clinical evidence to establish when the catheter should be removed. It is reasonable to wait until the patient is stable enough to reduce the risk of embolization during the most serious period.⁶

In the patient described, 7 days anticoagulation with heparin was sufficient for the disappearance of the thrombus; later treatment with acenocoumarol was started and lasted for 1 month. Fibrinolytic treatment was not used, as the clinical stability of the patient indicated a high risk to benefit coefficient.

Although the purpose of this report was to present the important role of TEE in the diagnosis and management of TCCV, this does not mean that it must be the primary diagnostic technique performed when there is a suspicion of TCCV, but that it should complement the results of the physical examination and other tests such as TTE. With continued technological progress TTE images will become sharper and provide more information about these lesions; therefore, a high

quality TTE should be performed first, and if this study is inconclusive, a TEE² should be performed.

REFERENCES

1. Roguin A, Reisner SA. Right atrial mass related to indwelling central venous catheters in patients undergoing dialysis. *Eur J Echocardiography* 2000; 1: 222-223.
2. Gilon D. Infected thrombi in the right atrium related to central venous catheters: an ongoing challenge. *Eur J Echocardiography* 2000; 1: 151.
3. Black IH, Blosser SA, Murray WB. Central venous pressure measurements: Peripherally inserted catheters versus centrally inserted catheters. *Crit Care Med* 2000; 28: 3833-3836.
4. Guindo J, Montagud M, Carreras F, Domínguez JM, Bartolucci J, Martínez-Ruiz MD et al. Fibrinolytic therapy for superior vena cava and right atrial thrombosis: diagnosis and follow-up with bi-plane transesophageal echocardiography. *Am Heart J* 1992; 124: 510-513.
5. Randolph AG, Cook DJ, Gonzales CA, Andrew M. Benefit of heparin in central venous and pulmonary artery catheters: a meta-analysis of randomized controlled trials. *Chest* 1998; 113: 165-171.
6. Weber T, Huemer G, Tschernich H, Kranz A, Imhof M, Sladen RN. Catheter-induced thrombus in the superior vena cava diagnosed by transesophageal echocardiography. *Acta Anaesthesiologica Scandinavica* 1998; 42: 1227-1230.
7. Puel V, Caudry M, Le Metayer P, Baste JC, Midy D, Marsault L. Superior vena cava thrombosis related to catheter malposition in cancer chemotherapy given through implanted ports. *Cancer* 1993; 72: 2248-2252.
8. Fassin D, Wechsler B, Herson S, Godeau P. Tromboses caves et maladies de système. *Ann Med Interne (Paris)* 1986; 137: 456-460.
9. Berman WJ, Fripp RR, Yabek SM, Wernly J, Corlew S. Great vein and right atrial thrombosis in critically ill infants and children with central venous lines. *Chest* 1991; 99: 963-967.
10. Tanke RB, Van Megen R, Daniels O. Thrombus detection on central venous catheters in the neonatal intensive care unit. *Angiology* 1994; 45: 477-480.
11. Jacobs B, Barr L, Brill R, Lyon SK, Wong H. Intracatheter nitroglycerin infusion fails to prevent catheter-related venous thrombosis: a randomized, controlled trial. *Intensive Care Med* 2001; 27: 187-192.
12. Raad II, Luna M, Khalil SA, Costerton JW, Lam C, Bodey GP. The relationship between the thrombotic and infectious complications of central venous catheters. *JAMA* 1994; 271: 1014-1016.
13. Cohen GI, Klein AL, Chan KL, Stewart WJ, Salcedo EE. Transesophageal echocardiographic diagnosis of right-sided cardiac masses in patients with central lines. *Am J Cardiol* 1992; 70: 925-929.
14. Bautista A, Goñi MV, Maestre A. Tromboembolismo pulmonar hemodinámicamente inestable. *Arch Bronconeumol* 2000; 36: 28-34.
15. Fernández JA, Ayuela JM, Fernández de Almeida CA, Aldea J, Fernández JL, Zabalegui A. Trombos gigantes intracavitarios secundarios a un «síndrome de trombocitopenia-trombosis inducido por heparina». *Rev Esp Cardiol* 1999; 52: 269-272.
16. Baci S, De Palma R, Visentin GP, Gorski J, Aster RH. Complexes of heparin and platelet factor 4 specifically stimulate T cells from patients with heparin-induced thrombocytopenia/thrombosis. *Blood* 1999; 94: 208-215.
17. Cabestrero D, Gálvez MA, Martín C, Cidoncha M, García de Lorenzo A. Heparinas de bajo peso molecular en pacientes críticos: usos, indicaciones y tipos. *Med Intensiva* 2001; 25: 18-26.