

Cardiogenic Shock Due to Dynamic Left Ventricular Outflow Tract Obstruction as a Mechanical Complication of Acute Myocardial Infarction

Antonio García Quintana, José R. Ortega Trujillo, Alfredo Padrón Mújica^a, Ricardo Huerta Blanco, Leonor González Morales^a and Alfonso Medina Fernández-Aceytuno

Servicio de Cardiología. ^aUnidad de Medicina Intensiva.
Hospital de Gran Canaria Dr. Negrín. Las Palmas de Gran Canaria. España.

We report the clinical case of a 77-years-old woman with cardiogenic shock caused by dynamic left ventricular outflow tract (LVOT) obstruction that appeared after anterior acute myocardial infarction. Dynamic LVOT obstruction has been reported in various circumstances aside from hypertrophic obstructive cardiomyopathy, such as acute myocardial infarction. In a patient with cardiogenic shock and a heart murmur after acute myocardial infarction, an acute mechanical complication, ventricular septal defect, and acute mitral regurgitation must be ruled out because the treatment of these conditions differs completely. We describe the diagnostic and therapeutic measures used in the diagnosis and treatment of this complication.

Key words: *Myocardial infarction. Shock. Subaortic stenosis. Echocardiography.*

Full English text available at: www.revespcardiol.org

Shock cardiogénico secundario a obstrucción dinámica del tracto de salida del ventrículo izquierdo como complicación mecánica del infarto agudo de miocardio

Presentamos el caso clínico de una mujer de 77 años con shock cardiogénico secundario a la obstrucción dinámica del tracto de salida del ventrículo izquierdo (TSVI) tras un infarto de miocardio anterior. La obstrucción dinámica del TSVI se ha descrito en diversas circunstancias al margen de su presentación clásica en el contexto de la miocardiopatía hipertrófica obstructiva, siendo una de ellas el infarto agudo de miocardio. Ante un paciente con shock cardiogénico tras un infarto de miocardio y soplo cardíaco es preciso descartar una complicación mecánica del mismo, comunicación interventricular o insuficiencia mitral aguda, porque el tratamiento de éstas es totalmente distinto. Describimos las medidas diagnósticas y terapéuticas necesarias para diagnosticar y tratar esta complicación.

Palabras clave: *Infarto de miocardio. Shock. Estenosis subaórtica. Ecocardiografía.*

INTRODUCTION

We report the case of a patient who was hospitalized for chest pain in the context of acute coronary syndrome with elevation of cardiac enzymes and electrocardiographic changes compatible with acute anterior myocardial infarction. The condition was complicated by hypotension and cardiogenic shock due to the presence of a dynamic obstructive gradient in the left ventricular outflow tract (LVOT), accom-

panied by moderate mitral insufficiency (MI) and left ventricular (LV) dysfunction due to anterior septo-apical akinesia.

Dynamic LVOT obstruction has traditionally been described in the context of obstructive hypertrophic cardiomyopathy (OHCM),¹ as due to asymmetrical septal hypertrophy accompanied by an anterior displacement of the mitral valve during the systole. Nevertheless, LVOT obstruction can appear in other situations, so if ventricular systolic function becomes hyperdynamic in a patient with basal septal hypertrophy, LVOT obstruction can occur much as in OHCM.^{2,3} In the case of myocardial infarction, a compensatory hyperkinesia of the preserved segments takes place, which is how the hyperkinetic basal septum causes LVOT obstruction. The treatment usually used in cardiogenic shock, such as inotropic

Correspondence: Dr. A. García Quintana.
Servicio de Cardiología. Hospital de Gran Canaria Dr. Negrín.
Bco. La Ballena, s/n. 35020 Las Palmas de Gran Canaria. España.
E-mail: antoniogarcia@secardiologia.es

Received 22 March 2002.
Accepted for publication 30 August 2002.

ABBREVIATIONS

TEE: transesophageal echocardiogram.
 TTE: transthoracic echocardiogram.
 EF: ejection fraction.
 VSD: ventricular septal defect.
 MI: mitral insufficiency.
 OHCM: obstructive hypertrophic cardiomyopathy.
 LVOT: left ventricular outflow tract.
 LV: left ventricle.

drugs (dopamine, epinephrine, dobutamine) or intra-aortic balloon counterpulsation, is contraindicated. Consequently, treatment is based on the use of drugs that reduce the gradient, like beta-blockers, pure alpha agonists, methoxamine, or phenylephrine, while volume depletion and the use of vasodilators is avoided.⁴

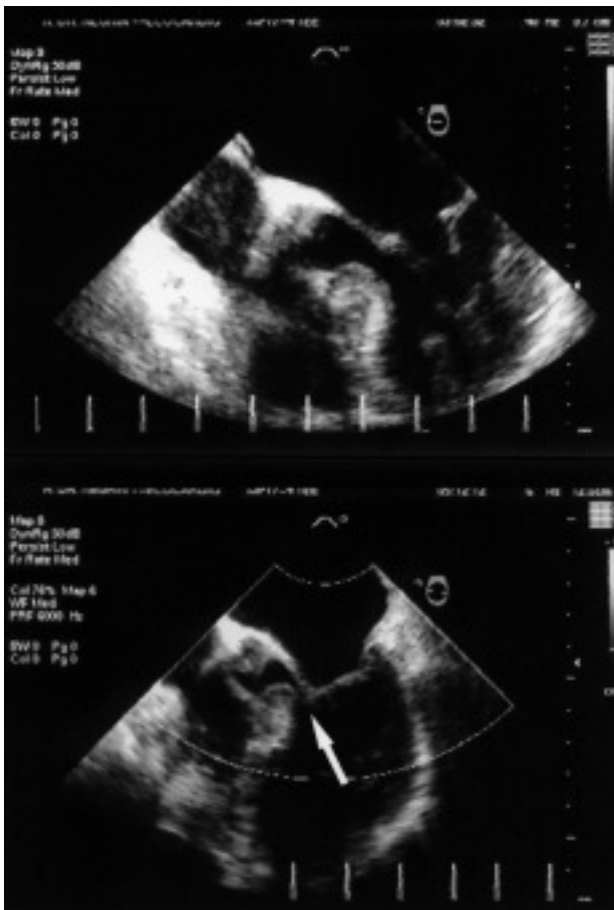

Fig. 1. Images of transesophageal echocardiography, diastole (upper image) and systole (lower image), in which hypertrophy of the basal septum and displacement of anterior leaflet of the mitral valve obstructing the LVOT (arrow) can be appreciated.

CLINICAL CASE

A 77-year-old woman with a history of arterial hypertension, under treatment with diuretics, was seen in the emergency room for chest pain at rest. The electrocardiogram showed a 1 mm elevation of the ST segment in V1-3, V6, and aVL, ST-segment depression in II, III, and aVF, and negative T waves in I, aVL, and V2. She had elevation of the cardiac enzymes, creatine kinase (CK) 275 U/L, and troponin I 14.67 ng/mL. While she remained in the emergency room, she presented hypotension, which was managed by volume expansion with colloids and dopamine infusion. The patient remained hypotensive and tachycardic, developing acute lung edema. Auscultation disclosed a 3/6 systolic murmur in the apex that radiated to the armpit, and bilateral crepitations of the bases, up to the middle fields. Her condition resolved after dopamine was discontinued and she was treated with furosemide, but she again presented hypotension and exacerbation of heart failure. An echocardiogram was performed with the patient seated, because she could not tolerate the supine position. Severe LV dysfunction was observed, with anterior septo-apical akinesia and an ejection fraction (EF) of approximately 30%, preserved contractility of the basal segments, and signs of moderate-to-severe MI. The patient's condition deteriorated and orotracheal intubation and mechanical ventilation was necessary. Suspecting a mechanical complication with severe LV dysfunction, an intra-aortic counterpulsation balloon was inserted and catecholamines were administered. Still, the patient's condition did not improve. Transesophageal echocardiography was performed to exclude a mechanical complication, which confirmed a moderate MI and no evidence of a ventricular septal defect (VSD). A thickened (approximately 17 mm), hyperdynamic basal septum with anterior septal displacement of the mitral valve was appreciated (Figure 1). Since the gradient of the outflow tract cannot be recorded by transesophageal echocardiography (TEE), a transthoracic echocardiogram was made (TTE). A peak gradient of approximately 90 mm Hg was recorded. With the Swan-Ganz catheter, no oximetric jump was observed and pulmonary wedge pressure was 18 mm Hg, central venous pressure was 17 mm Hg, and the cardiac index was 1.4 L/min/m². Cardiac catheterization revealed coronary arteries free of lesions and severe LV dysfunction, with an EF of 31%, a hypertrophic septum, LVOT gradient of 12.5 mm Hg, and LV end-diastolic pressure of 35 mm Hg. Given the presence of a dynamic LVOT gradient, catecholamines were discontinued, the counterpulsation balloon was removed, norepinephrine and methoxamine were given, 1-5 mg hourly, and intravascular volume expansion was carried out. Previously, treatment with esmolol was tried without observing any benefit. Another echocardiogram made after administering

methoxamine showed a significant reduction in the gradient, as well as an increase in the post-extrasystolic gradient (Figure 2 B and C). Likewise, the patient presented atrial fibrillation with hemodynamic deterioration, which required external electrical cardioversion and amiodarone, 300 mg, and continuous infusion of 900 mg/24 h. The patient persisted with heart failure and a systolic murmur, beginning treatment with atenolol, 12.5 mg/12 h, and increasing the dose up to 50 mg/12 h. The clinical manifestations of heart failure and the murmur disappeared. In an echocardiogram made 15 days later, left ventricular function had recovered, without zones of hypokinesia, with an EF of 55% by acoustic quantification, and no hypertrophy except in the basal septum. Likewise, the elevated LVOT gradient was not apparent and was not inducible with the Valsalva maneuver, even with beta-blocker treatment.

DISCUSSION

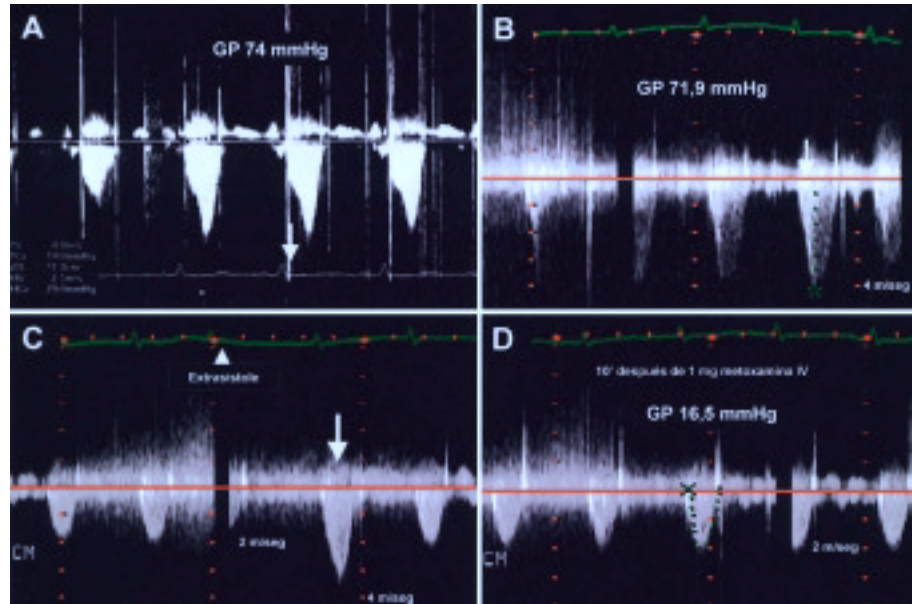
In the absence of OHCM, the diagnosis of dynamic LVOT obstruction has two requisites: *a*) the existence of hypertrophy of the basal septum, and *b*) a hyperdynamic left ventricular situation. This tends to occur most frequently in older patients with a history of hypertension and left ventricular hypertrophy, although hypertension is not an indispensable requirement. Another clinical group is constituted by patients with volume depletion in the postoperative period who have been treated with inotropic agents. Patients with aortic stenosis after valve replacement surgery are especially vulnerable to this form of LVOT obstruction,^{5,6} which is associated with a greater morbidity and mortality,^{7,8} as are patients in which mitral valve reconstruction surgery has been performed.⁹ Cases have been reported in patients with cardiac amyloidosis,² pheochromocytoma, balloon counterpulsation, or after anteroapical myocardial infarction in the presence of previous basal septum hypertrophy, and even myocardial ischemia alone.^{10,11} In the case of myocardial infarction, a compensatory hyperkinesia of the preserved segments takes place, which is how the hyperkinetic basal septum causes LVOT obstruction.¹² The fact that cases have been reported of patients with lesion-free coronary arteries^{4,13} has led some authors to propose dynamic LVOT obstruction as the trigger of myocardial damage, although the existence of a thrombus that lyses before coronariography, or vasospasm, cannot be excluded. Compensatory hyperkinesia of non-infarcted segments in the context of acute myocardial infarction is a frequently observed phenomenon, which tends to disappear as the function of the ischemic myocardium recovers. The follow-up of some of these patients shows the resolution of the motility anomalies of the wall, as well as disappearance of the LVOT gradient, which could not be induced la-

ter.¹⁴ The pathophysiological mechanism proposed to explain the appearance of secondary ischemia would be the presence of a thickened basal septum and certain circumstances (hypovolemia, hypercontractility, tachycardia, etc.) that cause dynamic LVOT obstruction and, consequently, an increase in intraventricular pressure, with reduction of the myocardial oxygen supply/demand that gives rise to ischemia. As a compensatory response to ischemia, hypercontractility of the basal segments is generated, which produces more LVOT obstruction and maintains this situation. Patients with a sigmoid interventricular septum, small LVOT, and reduced left ventricular volumes, mainly women, as well as an abnormal orientation of a flaccid mitral valve structure, have a geometric predisposition to dynamic LVOT obstruction, which can be manifested in the context of intense adrenergic stimulation or hypovolemia.¹⁵ Recently, a syndrome has been described that clinically and electrocardiographically simulates acute myocardial infarction, with minimal elevation of cardiac enzymes. It is characterized by ischemia of the apical region, which acquires a blown-up shape (*apical ballooning*) in the absence of coronary disease. It produces an increase in the mid-ventricular gradient, not in the LVOT, without appearing to have hemodynamic consequences,¹⁶ and is attributed fundamentally to vasospasm.

Transthoracic echocardiography should be considered the technique of choice for excluding the existence of an obstructive dynamic LVOT gradient, also confirming the presence of MI and anterior systolic displacement of the mitral valve. The morphology of the Doppler curve shows delayed acceleration, which is characteristic of subaortic dynamic obstruction (Figure 2A and B). The echocardiogram makes it possible to exclude other mechanical complications of infarction, like VSD or acute MI. Estimation of the gradient in the hemodynamics laboratory is carried out with a catheter with a distal orifice to aid in locating it.

Treatment differs from the usual treatment for cardiogenic shock. The use of vasodilators, reduction of postload, and inotropic agents must be avoided. Therapeutic measures in this case include the administration of beta-blockers that act to reduce the hyperkinesia of the basal segment, helping to reduce the LVOT gradient; pure alpha-agonists like methoxamine, a drug that acts preferentially on alpha 1 receptors, producing intense vasoconstriction and an increase in blood pressure, with reflex bradycardia, giving rise to a greater functional LVOT and decrease in the gradient. The decrease in the gradient with methoxamine administration was confirmed by echocardiography (Figure 2D). Tachyarrhythmias must be treated aggressively, fundamentally atrial fibrillation, electrical cardioversion should be used to restore sinus rhythm and

Fig. 2. Continuous Doppler tracings through the LVOT. A: the characteristic morphology of delayed acceleration of the dynamic LVOT obstruction is evident. B: gradient before methoxamine administration (peak gradient 72 mm Hg). C: an increased post-extrasystolic gradient is appreciated after a supra-ventricular extrasystole, which was expressed clinically as a decrease in pulse pressure (Brockenbrough-Braunwald phenomenon). D: decrease in the gradient 10 minutes after administration of 1 mg IV of methoxamine (peak gradient 16.5 mm Hg).



amiodarone should be given.

In a patient with acute myocardial infarction, the presence of hypotension and a murmur of new appearance suggests the development of a mechanical complication, acute MI, or VSD. Nevertheless, dynamic LVOT obstruction can appear as a complication of infarction and show similar manifestations. Transthoracic echocardiography, and transesophageal echocardiography if an optimal image is not obtained, is the diagnostic technique of choice. Predictors of acquired dynamic LVOT obstruction are acute infarction of the anterior myocardium that originates apical hypokinesia, compensatory basal hyperkinesia, mild concentric LV hypertrophy and, possibly, single-vessel coronary artery disease, since multivessel disease could prevent the development of baseline hyperkinesia.

REFERENCES

- Candell Riera J, Romero Farina G, Galve Basilio E, Palet Balart J, Armadans L, García del Castillo H, et al. Valor del ecocardiograma-Doppler en el pronóstico y en el seguimiento de la miocardiopatía hipertrófica. *Rev Esp Cardiol* 2001;54:7-15.
- Oh JK, Seward JB, Tajik AJ. *The echo manual*. 2nd ed. Rochester: Lippincott Williams & Wilkins, 1999; p. 162.
- Romero-Farina G, Candell-Riera J, Pereztol-Valdés O, Aguadé-Bruix S, Castell-Conesa J, Armadans L, et al. Tomogammagrafía miocárdica de esfuerzo en los pacientes con miocardiopatía hipertrófica. *Rev Esp Cardiol* 2000;53:1589-95.
- Haley JH, Sinak LJ, Tajik AJ, Ommen SR, Oh JK. Dynamic left ventricular outflow tract obstruction in acute coronary syndromes: an important cause of new systolic murmur and cardiogenic shock. *Mayo Clin Proc* 1999;74:901-6.
- Aurigemma G, Battista S, Orsinelli D, Sweeny A, Pape L, Cuenoud H. Abnormal left ventricular intracavitary flow acceleration in patients undergoing aortic valve replacement for aortic stenosis: a marker for high postoperative morbidity and mortality. *Circulation* 1992;86:926-36.
- López Ayerbe J, Evangelista Masip A, Armada Romero E, Mateos González M, González Alujas MT, García del Castillo H, et al. Aparición de gradiente dinámico intraventricular después de la sustitución valvular aórtica en pacientes con estenosis aórtica severa. *Rev Esp Cardiol* 2002;55:127-34.
- Morewood GH, Weiss SJ. Intra-aortic balloon pump associated with dynamic left ventricular outflow tract obstruction after valve replacement for aortic stenosis. *J Am Soc Echocardiography* 2000;13:229-31.
- Bartunek J, Sys SU, Rodrigues AC, Van Schuerbeeck E, Mortier L, de Bruyne B. Abnormal systolic intraventricular flow velocities after valve replacement for aortic stenosis. Mechanisms, predictive factors, and prognostic significance. *Circulation* 1996; 93:712-9.
- Maslow AD, Regan MM, Haering JM, Johnson RG, Levine RA. Echocardiographic predictors of left ventricular outflow tract obstruction and systolic anterior motion of the mitral valve after mitral valve reconstruction for myxomatous valve disease. *J Am Coll Cardiol* 1999;34:2096-104.
- Villareal RP, Achari A, Wilansky S, Wilson JM. Anteroapical stunning and left ventricular outflow tract obstruction. *Mayo Clin Proc* 2001;76:79-83.
- Kuo LT, Wang CH, Hung MJ, Cherng WJ. Coronary vasospasm inducing dynamic left ventricular outflow tract obstruction. *Tex Heart Inst J* 2001;28:223-5.
- Landesman KA, Sadaniantz A. Left ventricular outflow tract obstruction after myocardial infarction due to a hyperdynamic basal septum. *Echocardiography* 2001;18:291-4.
- San Román Sánchez D, Medina O, Jiménez F, Rodríguez JC, Nieto V. Dynamic intraventricular obstruction in acute myocardial infarction. *Echocardiography* 2001;18:515-8.
- Joffe II, Riley MF, Katz SE, Ginsburg GS, Douglas PS. Acquired dynamic left ventricular outflow tract obstruction complicating acute anterior myocardial infarction: serial echocardiographic and clinical evaluation. *J Am Soc Echocardiography* 1997;10:717-21.
- Krasnow N. Subaortic septal bulge simulates hypertrophic cardiomyopathy by angulation of the septum with age, independent of focal hypertrophy. An echocardiographic study. *J Am Soc Echocardiogr* 1997;10:545-55.
- Tsuchihashi K, Ueshima K, Uchida T, Oh-mura N, Kimura K, Owa M, et al. Transient left ventricular apical ballooning without coronary artery stenosis: a novel heart syndrome mimicking acute myocardial infarction. Angina Pectoris-Myocardial Infarction Investigations in Japan. *J Am Coll Cardiol* 2001;38:11-8.