

Cardiac Perforation Complicated by Cardiac Tamponade and Sealed With Metallic Coils

Vicens Martí,^a Carlos Castaño^b, Pere Guiteras^a, Ermengol Vallés^a, José M. Domínguez de Rozas,^a and Josep M. Augé^a

^aServicio de Cardiología, Hospital de la Santa Creu i Sant Pau, Barcelona, Spain.

^bServicio de Radiodiagnóstico, Hospital de la Santa Creu i Sant Pau, Barcelona, Spain.

Distal coronary artery perforation with an angioplasty guidewire is a rare complication that may cause cardiac tamponade, myocardial infarction, arrhythmia, and even death. The use of platelet IIb/IIIa glycoprotein receptor inhibitors increases the risk of potentially fatal complications that are difficult to manage. We report a patient on treatment with abciximab who presented coronary perforation in a distal branch of the right coronary artery caused by the coronary guidewire tip, and complicated by acute cardiac tamponade. Blood extravasation to the pericardium was stopped by releasing two metallic coils into the distal vessel, thereby avoiding the need for emergent cardiac surgery.

Key words: *Coronary angioplasty. Pericardium. Coronary perforation.*

Full Spanish text available at: www.revespcardiol.org

INTRODUCTION

Coronary artery perforation is a rare complication of coronary surgery that generally occurs when the guidewire crosses complex lesions or when devices such as an atherotome or laser are used.^{1,2} The more frequent use of platelet glycoprotein IIb/IIIa receptor inhibitors (GPIIb/IIIa) greatly increases the risk of severe hemorrhaging, which can cause acute cardiac tamponade which is of difficult management. We report on a patient treated with abciximab who presented perforation of a distal branch of the right coronary artery during angioplasty, followed by acute cardiac

Perforación coronaria complicada con taponamiento cardíaco sellada mediante *coils* metálicos

La perforación coronaria con la guía de angioplastia es una complicación rara que puede ocasionar taponamiento cardíaco, infarto, arritmias e incluso la muerte. La utilización de fármacos inhibidores de los receptores glucoproteicos IIb/IIIa de las plaquetas aumenta considerablemente el riesgo de complicaciones agudas y dificulta el manejo terapéutico. Describimos el caso de un paciente tratado con abciximab que durante la angioplastia presentó una perforación en una rama distal de la arteria coronaria derecha producida con la punta de la guía, que se complicó con taponamiento cardíaco agudo. El sangrado al pericardio se resolvió mediante la liberación de 2 *coils* o espirales metálicas en la luz distal del vaso perforado, y se evitó la cirugía emergente.

Palabras clave: *Angioplastia coronaria. Pericardio. Perforación coronaria.*

tamponade. Pericardial bleeding was resolved by placement of 2 metal coils in the distal lumen of the vessel.

CASE STUDY

A 50-year-old man with a history of smoking and exertional angina of one week evolution presented in the emergency department at night for precordial pain at rest. The electrocardiogram (ECG) showed ascending ST segment elevation of 1 mm, with the J point on the isoelectric line, and Q wave in leads II and III. Creatine kinase elevation was 471 U/L. The patient was diagnosed with acute inferior wall myocardial infarction, and transferred, asymptomatic, to the coronary care unit. Coronary angiography was performed 12 hours after admission; thrombotic obstruction of the middle right coronary artery (RCA) was visualized, indicating the need for angioplasty. Sodium heparin (7000 U) was administered intravenously along with abciximab in a bolus dose of 0.25

Correspondence: Dr. V. Martí.
Unidad de Hemodinámica. Servicio de Cardiología.
Hospital de la Santa Creu i Sant Pau.
Avda. Antoni M. Claret, 167. 08025 Barcelona. España.
E-mail: 18461vmc@comb.es

Received October 30, 2003.
Accepted for publication April 28, 2004.

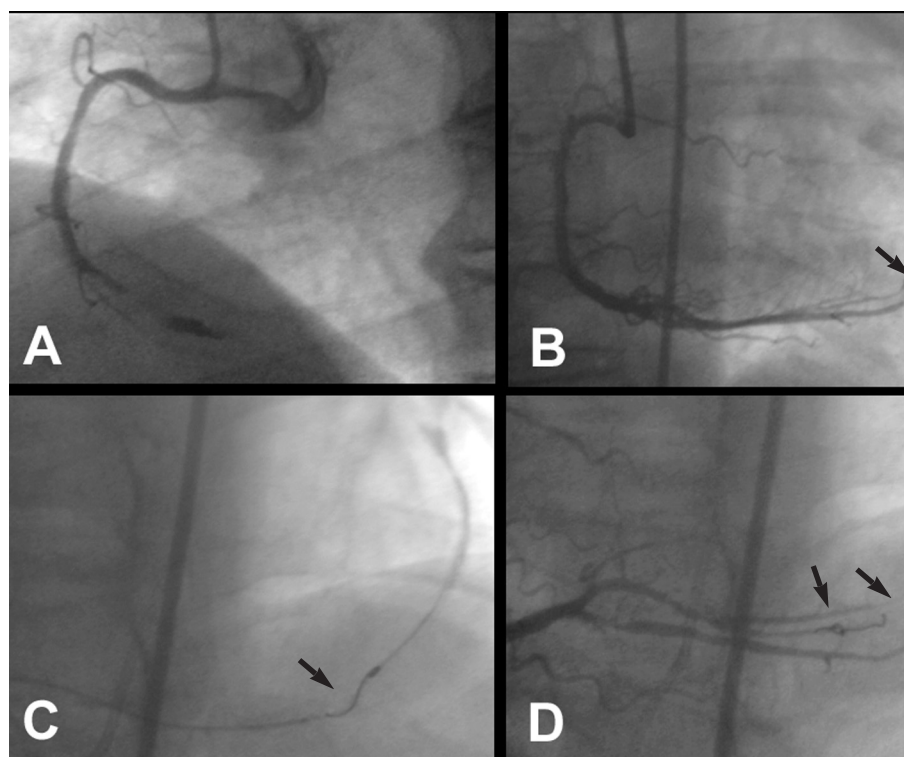


Fig. 1. A: right coronary artery after thrombectomy. An image suggestive of intracoronary thrombus is observed. B: thread-like extravasation of contrast material to the pericardium (arrow) due to perforation of a distal arteriole by the angioplasty guidewire. C: fluoroscopic image showing placement of a metal coil (arrow) in the perforated vessel. D: resolution of extravasation image after placement of a second coil (arrows).

mg/kg weight, followed by continuous perfusion at 10 μ g/min. After crossing the occlusion with a hydrophilic-coated guidewire 3 aspirations using a 1.5 mm diameter X-Sizer thrombectomy device was performed (Figure 1A). Two coronary stents of 2.75 \times 14 mm in the distal third and 3.0 \times 18 mm in the middle third were subsequently implanted with good results. However, one of the immediate coronary angiographies showed thread-like extravasation of contrast material at the distal end of a distal arteriole of the right coronary artery (Figure 1B). Shortly afterwards, the patient presented sudden hypotension (40 mm Hg) due to cardiac tamponade that required emergent pericardiocentesis and drainage, which yielded 600 mL of blood. Protamine was administered and abciximab perfusion was discontinued. Mechanical hemostasis was accomplished by inflating a 1.5 mm diameter angioplasty balloon in the branch of the posterolateral artery proximal to the perforation. Multiple inflations were performed at low atmospheres for 4-5 min. Since extravasation of contrast medium to the pericardium persisted, a metal coil (Vortx[®] Fibered Platinum, Boston Scientific, Natick, Massachusetts, USA) was placed using a 2.3 Fr catheter (Rapid Transit, Cordis, Miami, Florida, USA) located in the distal branch of the perforated right coronary artery (Figure 1C). Because a small thread-like extravasation still persisted, a second coil was implanted. The absence of extravasation was confirmed in a repeat angiography (Figure 1). The ECG showed persistence

of Q-wave in leads II and III, as well as a slight ST segment alteration in the posterolateral inferior wall, with posterior and lateral normalization after transfusion of packed red blood cells. Troponin values were positive. The following morning, the echocardiogram showed no pericardial effusion, and the drainage was removed. The patient was discharged at 48 hours. Four months later, stress testing was negative for ischemia.

DISCUSSION

The incidence of cardiac perforation during angioplasty is 0.2%, but can be as high as 3% when devices such as an atherotome or laser are used.^{1,3} In 20% of cases,¹ the angioplasty guidewire is the cause. According to Ellis et al,⁴ cardiac perforation can be classified into one of four types: Type I: extraluminal crater without extravasation; Type II: pericardial or myocardial blushing without contrast streaming; Type III: extravasation through perforation >1 mm with contrast streaming, and Type CS: cavity spilling when the extravasation streams toward an anatomical cavity. Although perforation may not result in symptoms and may be contained, it sometimes causes serious acute complications such as cardiac tamponade, myocardial infarction, malignant arrhythmias, and occasionally death. Early onset of pericardial effusion is associated with a worse prognosis since one third of these patients require emergent surgery, either because pericar-

diocentesis is ineffective or because the arterial injury must be repaired.^{1,5}

Coronary artery perforation is more frequent when hydrophilic-coated guidewires are used, as occurred with our patient. These guidewires are very useful for crossing severe stenoses, but are unfortunately associated with a higher risk of arterial perforation, particularly when trying to cross complex lesions such as occlusions, bifurcations, long lesions, and tortuous vessels.⁶ In the patient we describe, the mechanism causing the perforation could have been the hydrophilic-coated guidewire or the inadvertent advance of the guidewire during the thrombectomy. On occasions, protamine administration and prolonged balloon inflation are enough to stop the bleeding.^{1,2} However, treatment with GPIIb/IIIa inhibitors limits the effectiveness of these hemostasis mechanisms. In patients in whom the extravasation is located in the wall of a small or large epicardial artery, it is usually effective to cover the perforation with a stent-graft.⁷ Nevertheless, in tertiary branches, arterioles or small distal vessels, other therapeutic measures aimed at occlusion of the distal vessel by either thrombosis or embolization are necessary. In addition to coils,⁸ precoagulated autologous blood, gelfoam and intracoronary thrombin have been used for this purpose in isolated cases.⁹⁻¹¹ In our patient we used 2 platinum coils to stop the bleeding to the pericardium. The small changes in enzyme levels we observed after placing the coils were attributed to implantation as distal as possible in the posterolateral artery branch, thereby compromising a small amount of myocardial tissue, as well as the possibility that some infarcted tissue was already present in part of the territory. We should point out that the use of these devices, which are prone to thrombosis, should be limited to perforations of distal arterioles because they produce complete occlusion of the vessel lumen, with the resulting risk of infarction. This technique has recently been used as a successful elective procedure to occlude the first septal branch of the left anterior descending artery, in order to cause septal infarction in patients with hypertrophic obstructive cardiomyopathy.¹²

In summary, the technique we describe has the advantage of being fast and effective in sealing coronary perforation of a distal arteriole, avoiding the need for emergent surgery.

REFERENCES

1. Ajluni SC, Glazier S, Blankenship L, O'Neill WW, Safian RD. Perforations after percutaneous coronary interventions: clinical, angiography therapeutic observations. *Cathet Cardiovasc Diagn* 1994;32:206-12.
2. Flynn MS, Aguirre FV, Donohue TJ, Bach RG, Caracciolo EA, Kern MJ. Conservative management of guidewire coronary perforation with pericardial effusion during angioplasty for acute myocardial infarction. *Cathet Cardiovasc Diagn* 1993;29:285-8.
3. Elsner M, Zeiher AM. Perforation and rupture of coronary arteries. *Herz* 1998;23:311-8.
4. Ellis SG, Ajluni S, Arnold AZ, Pompa JJ, Bittle JA, Eigler NL, et al. Increased coronary perforation in the new device era, incidence, classification, management, and outcome. *Circulation* 1994; 90:2725-30.
5. Goldbaum TS, Jacob AS, Smith DF, Pichard A, Lindsay J. Cardiac tamponade following percutaneous transluminal coronary angioplasty: four case reports. *Cathet Cardiovasc Diagn* 1985; 11:413-6.
6. Wong CM, Mak GY, Chung DT. Distal coronary artery perforation resulting from the use of hydrophilic coated guidewire in tortuous vessels. *Cathet Cardiovasc Diagn* 1998;44:93-6.
7. Chae JK, Park SW, Kim YH, Hong MK, Park SJ. Successful treatment of coronary artery perforation during angioplasty using autologous vein graft-coated stent. *Eur Heart J* 1997;18:1030-2.
8. Gaxiola E, Browne KF. Coronary artery perforation repair using microcoil embolization. *Cathet Cardiovasc Diagn* 1998;43:474-6.
9. Finch JJ, Krouse JR. Pericardial tamponade from iatrogenic coronary artery perforation treated with transcatheter embolization. *J Vasc Intervent Radiol* 1996;7:147-8.
10. Cordero H, Gupta N, Underwood PL, Gogste ST, Hauser RR. Intracoronary autologous blood to seal a coronary perforation. *Herz* 2001;26:157-60.
11. Fischell TA, Korban EH, Lauer MA. Successful treatment of distal coronary guide-wire-induced perforation with balloon catheter delivery of intracoronary thrombin. *Cathet Cardiovasc Diagn* 2003;58:370-4.
12. Rodrigo D, Montes PM, Alcibar J, Fernández J, Gómez S, Barrenetxea JJ. Oclusión con micro-coils de la primera rama septal en el tratamiento de un paciente con miocardiopatía hipertrófica obstructiva. *Rev Esp Cardiol* 2003;56:1232-4.