

Cardiac Injury after Indirect Lightning Strike

Francisco J. Ruiz Ruiz, Fernando J. Ruiz Laiglesia, Antonio Lobo Escolar, Ana M. Hualde Enguita, Carmen B. Torrubia Pérez and Eva Calvo Beguería

Servicio de Medicina Interna B. Hospital Clínico Universitario Lozano Blesa. Zaragoza.

Lightning strike is one of the most frequent causes of death due to natural phenomena. In such cases, cardiac injury is the main cause of death, with type of lesion varying by type of impact.

We report the case of a 29-year-old woman who was struck indirectly by lightning. Upon hospital admission, she showed both the echocardiographic disturbances characteristic of direct impact and electrocardiographic disturbances. Both types of change resolved spontaneously. After describing the case, we briefly review the literature on echo and electrocardiographic disturbances after lightning strike.

Key words: *Lightning strike. Electrocardiography. Echocardiography. Diagnosis.*

Full English text available at: www.revespcardiol.org

Alteraciones cardíacas en la fulguración por impacto indirecto

La fulguración es una de las causas más frecuentes de muerte por fenómenos naturales. La lesión cardíaca constituye la principal causa de mortalidad, dependiendo las lesiones producidas del tipo de impacto.

Presentamos el caso de una mujer de 29 años que sufrió fulguración por impacto indirecto. En el momento del ingreso presentaba alteraciones ecocardiográficas, lo cual es característico del impacto directo, y anomalías electrocardiográficas. Ambos cambios se resolvieron de forma espontánea. Tras la exposición del caso, realizamos una breve revisión de las alteraciones ecocardiográficas y electrocardiográficas tras la fulguración.

Palabras clave: *Fulguración. Electrocardiografía. Ecocardiografía. Diagnóstico.*

INTRODUCTION

Lightening strike is one of the most frequent causes of death by natural phenomena.¹ It is estimated that a third of lightening strike cases are mortal, and of those patients who survive 70% have permanent sequelae.² Disturbances of cardiac conduction are the principal cause of death.³ The cardiac effects in patients who survive, in addition to conduction disturbances, are electrocardiograph (ECG) changes, elevation of the creatin kinase MB fraction (CK-MB), contractility defects, and involvement of the pericardium.

There are 3 types of lightening strike: direct, indirect via air, and indirect via ground. The cardiac changes caused by lightening strike vary according to the impact.² We present the case of a 29-year-old woman

with cardiac changes secondary to an indirect lightning strike.

CLINICAL CASE

In the summer of 1999, during a storm, a married couple was struck by lightening while walking back to their home. The man died immediately, and the woman, 29 years old, was taken to the nearest hospital.

The patient had no significant medical history. Upon admission she presented with posttraumatic amnesia and agitation. She was found to be hemodynamically stable, with arterial pressures of 110/70 mm Hg and a heart rate of 100 beats/minute. On examination there were serpiginous burns that extended from the ribs to the left iliac bone.

An ECG was performed which revealed inversion of T-waves in the anterior surface that over the course of hours extended to the inferior surface (Figure 1). The CK number was 561 U/L with an MB fraction of 9 U/L. Twenty-four hours later the CK was 253 U/L and the MB fraction was 23 U/L. An echocardiogram was performed and revealed the existence of apical

Correspondence: Dr. F.J. Ruiz Ruiz.
Hospital Clínico Universitario Lozano Blesa.
Secretaría Medicina Interna «B».
Avda. San Juan Bosco, 15. 50009 Zaragoza. Spain.
E-mail: ruizruizfj@yahoo.es

Received 27 august 2001.

Accepted for publication el 16 november 2001.

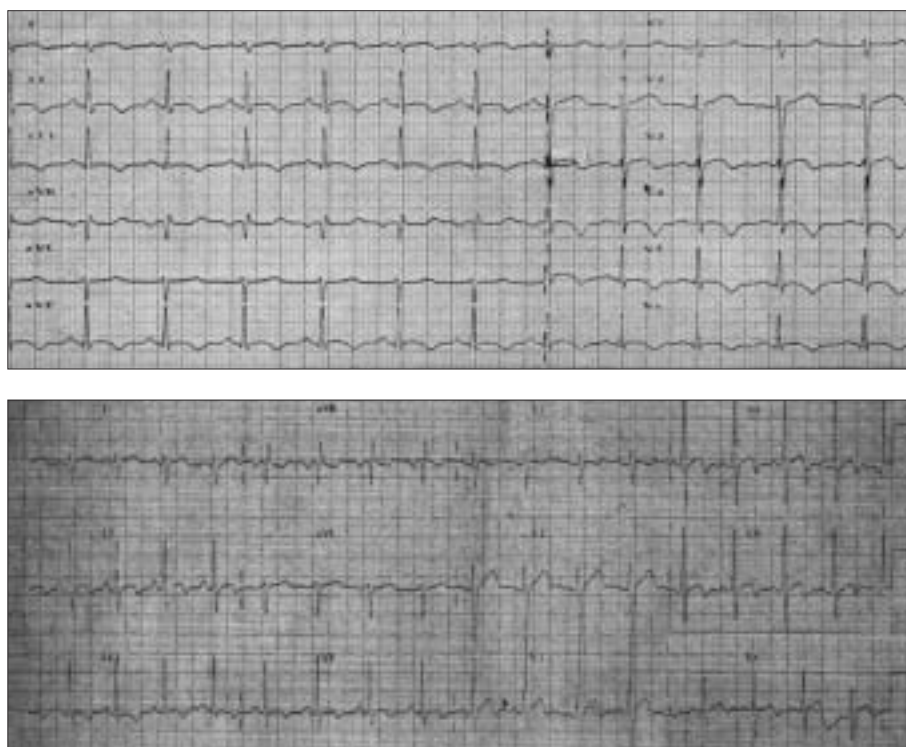


Fig. 1. In the upper part of the figure is the electrocardiogram on admission. The T-wave inversion on the anterolateral and inferior surfaces can be seen. In the lower part is the electrocardiogram on hospital discharge, in which the T-wave of the anterolateral surface has become biphasic, with the negative T-wave persisting on the inferior surface.

and apicolateral hypokinesia. Although the patient did not complain of chest pain at any point during the evaluation, due to the suspicion of myocardial ischemia she was transferred to our hospital. During admission the patient remained asymptomatic, without any other data than that already described being obtained on repeat evaluation. The serial cardiac enzymes were determined; they did not follow the pattern for myocardial ischemia and became normal. On ECG a tendency to positive T-wave on the anterior and lateral surfaces was observed, making the T-wave biphasic. Electrocardiogram at discharge was normal, without contractile changes. The patient lived in another autonomous community, making follow-up impossible after discharge.

DISCUSSION

The case we present causes doubts as to the ischemic myocardial effects of lightning strike.

Our patient suffered a typical indirect lightning strike.

Of note, in the study published by Lichtenberg,² only those subjects who suffered direct lightning strikes had echocardiography anomalies. These changes took the form of pericardial hemorrhage and severe overall dysfunction of cardiac motility. In some subjects, these lesions were reversible, although this was not always the case.⁴ None of the study patients who suffered an

indirect lightning strike had detectable echocardiography changes. In the case presented, the motility changes were not as severe as in the direct impact cases, and as occurred in some of them, the changes resolved spontaneously.

The ECG changes following lightning strike may appear in the absence of a significant decrease in motility and may not occur in the case of structural damage. They may translate into a banal occurrence or correspond to a potentially life-and-death situation.⁵

The changes most frequently described were sinus tachycardia and nonspecific ST segment and T-wave changes that generally resolved spontaneously in a matter of hours or days.^{6,7} Lengthening of the QT interval was also observed, but was more specifically seen with direct lightning strikes.²

The early appearance of inverted T-waves on the anterior and inferior surfaces, together with changes in cardiac motility lead to the suspicion of a non-ischemic myocardial lesion secondary to lightning strike. Said changes appear to be due more to autonomous instability than to a myocardial lesion.⁷

In our patient, there was no CK-MB elevation, but even if this had been the case, its interpretation would be difficult, as there is not always a correlation with clinical signs or ECG changes, and there is not a particular, uniform moment for its appearance. The initial elevation of the CK-MB fraction seems to have a more musculoskeletal origin than a cardiac origin.⁸

In those patients who suffered a lightning strike, the clinical picture may appear later, in the form of re-activate pericarditis, and on ECG findings typical of pericarditis can be seen.² In our opinion, the therapeutic management of these patients may be presumed to be in most aspects the same as for closed cardiac trauma.⁹

In the case we present, the differential diagnosis was simple, given the patient's age and the lack of antecedents. But there are cases in which differentiation of lesions produced by lightning strike from preexisting lesions may be complicated.

CONCLUSION

In indirect lightning strikes, echocardiography changes may be observed. These may be transitory and resolve spontaneously. Careful evaluation of the patient's course is indispensable for a correct diagnosis.

REFERENCES

1. Fontanarossa PB. Electrical shock and lightning strike. *Ann Emerg Med* 1993;22:378-87.
2. Lichtenberg R, Dries D, Ward K, Marshall W, Scanlon P. Cardiovascular effects of lightning strikes. *J Am Coll Cardiol* 1993;21:531-6.
3. Zack F, Hammer U, Klett I, Wegener R. Myocardial injury due to lightning. *Int J Legal Med* 1997;110:326-8.
4. Homma S, Gillam L, Weyman A. Echocardiographic observations in survivors of acute electrical injury. *Chest* 1990;97:103-5.
5. Carleton S. Cardiac problems associated with electrical injury. *Cardiol Clin* 1995;13:263-6.
6. Graber J, Ummenhofer W, Herion H. Lightning accident with eight victims: case report and brief review of the literature. *J Trauma* 1996;40:288-90.
7. Browne B, Gaasch W. Electrical injuries and lightning. *Emerg Med Clin North Am* 1992;10:211-28.
8. Lindemann J. Descarga eléctrica y por rayos. En: Sanz G, editor. *Alteraciones cardiovasculares en las enfermedades sistémicas*. Barcelona: Medical Trends, 1997; p. 177-80.
9. Echevarría JR, San Román A. Evaluación y tratamiento de los traumatismos cardíacos. *Rev Esp Cardiol* 2000;53:727-35.