

## Image in cardiology

## Cardiac Abnormalities in LEOPARD Syndrome

## Anomalías cardíacas en el síndrome de LEOPARD

Daniel García-Fuertes,\* Dolores Mesa-Rubio, and Manuel Crespín-Crespín

Servicio de Cardiología, Hospital Universitario Reina Sofía, Córdoba, Spain

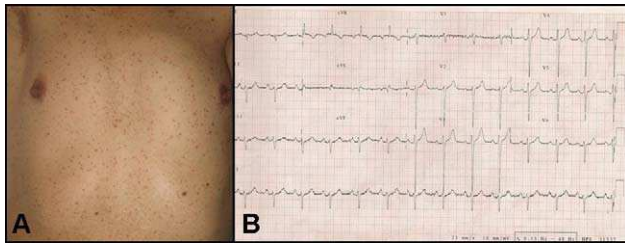


Figure 1.

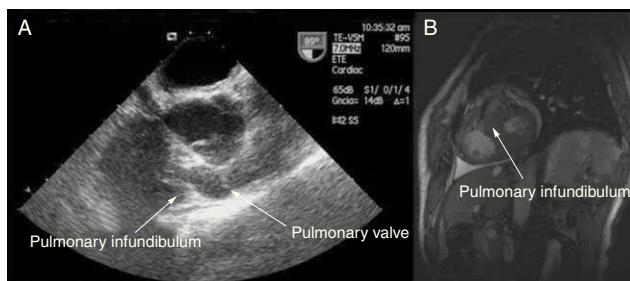


Figure 3.

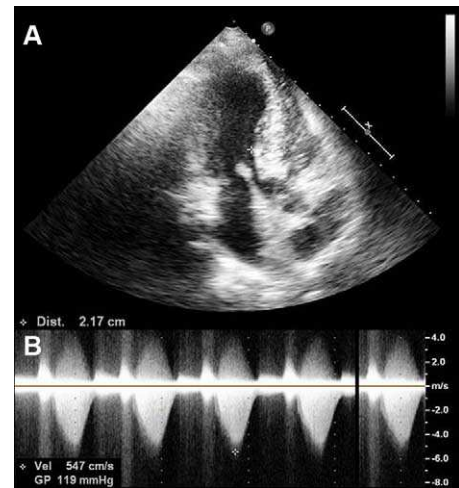


Figure 2.

LEOPARD syndrome is an autosomal dominant genetic disorder involving a complex of malformations and other features, including lentiginosis, electrocardiographic conduction abnormalities, ocular hypertelorism, pulmonary valve stenosis, abnormal genitalia, growth retardation, and sensorineural deafness. The most common cardiovascular manifestations of this condition are pulmonary valve stenosis, hypertrophic cardiomyopathy, and conduction disturbances.

We present the case of a 56-year-old man who was seen for dyspnea on minimal exertion. His clinical history was notable for a diagnosis of hypogonadism, and physical examination showed the presence of numerous lentiginos (Fig. 1A) and a holosystolic murmur at the left parasternal border. Electrocardiography showed signs of right atrial and left ventricular enlargement, as well as extreme right axis deviation (Fig. 1B). Echocardiography disclosed severe asymmetric septal hypertrophy of the left ventricle (septum, 21 mm) (Fig. 2A) and stenosis of the pulmonary infundibulum, which caused severe obstruction of the right ventricular outflow tract (maximum gradient, 119 mmHg) (Fig. 2B); the pulmonary valve anatomy was normal (Fig. 3A). Magnetic resonance imaging confirmed the origin of the obstruction (Fig. 3B).

Although pulmonary valve stenosis is the most commonly described cardiovascular anomaly in this syndrome, an infundibular location of the obstruction, as was seen in our patient, has been reported in some cases. Prompt diagnosis of this syndrome is essential because the concomitant cardiovascular anomalies can have a considerable influence on the prognosis.

\* Corresponding author:  
E-mail address: dani11gf@hotmail.com (D. García-Fuertes).  
Available online 4 March 2011