

Budd-Chiari Syndrome With Complete Occlusion of the Inferior Vena Cava: Percutaneous Recanalization by Angioplasty and Stenting

Ángel Sánchez-Recalde, Nicolás Sobrino, Guillermo Galeote, Luis Calvo Orbe, José L. Merino, and José A. Sobrino

Unidad Médico-Quirúrgica de Cardiología, Hospital Universitario La Paz, Madrid, Spain.

A 47-year-old man was diagnosed with primary antiphospholipid syndrome and Budd-Chiari syndrome (membranous complete obstruction of the intrahepatic inferior vena cava), with edema and ascites refractory to medical treatment. The inferior vena cava membrane was punctured with a Brockenbrough needle under multidirectional fluoroscopic guidance via a transfemoral approach. The occlusion was dilated with balloons of increasing size and was subsequently stented successfully. At 1-year follow-up venography showed patency of the stent, and the patient remains asymptomatic 2 years after the procedure.

Key words: *Angioplasty. Stent. Inferior vena cava. Budd-Chiari syndrome. Catheterization.*

Síndrome de Budd-Chiari por obstrucción completa de la vena cava inferior: recanalización percutánea mediante angioplastia e implante de *stent*

Presentamos el caso de un varón de 47 años diagnosticado de síndrome antifosfolipídico primario con síndrome de Budd-Chiari asociado (obstrucción completa membranosa de la vena cava inferior intrahepática), que presentaba ascitis y edemas rebeldes al tratamiento médico. Por vía percutánea se recanalizó la vena cava inferior atravesando la membrana con una aguja de Brockenbrough bajo guía fluoroscópica; posteriormente, se dilató con balones de tamaño creciente y, por último, se implantó un *stent* con éxito. En el control angiográfico realizado 1 año más tarde no se observó reestenosis y después de más de 2 años, el paciente se encuentra asintomático.

Palabras clave: *Angioplastia. Stent. Vena cava inferior. Síndrome de Budd-Chiari. Cateterismo cardíaco.*

INTRODUCTION

Budd-Chiari syndrome is a heterogeneous group of diseases characterized by occlusion of the hepatic veins or the inferior vena cava, producing portal hypertension. The most frequent cause in Western countries is thrombotic occlusion in a hypercoagulable state.¹ The present case illustrates percutaneous recanalization of complete inferior cava occlusion by angioplasty and stent implantation in a patient with primary antiphospholipid syndrome.

CASE STUDY

A 47-year old man with primary antiphospholipid syndrome and associated Budd-Chiari syndrome was hospitalized several times for abdominal pain, tension

ascites, and refractory edema, despite anticoagulant treatment and high doses of furosemide and spironolactone. Magnetic resonance angiography showed total occlusion of the inferior intrahepatic vena cava, immediately above the junction of the suprahepatic veins, which were patent. We were advised to attempt percutaneous recanalization.

The right femoral and internal jugular veins were canalized and a complete membranous obstruction was observed in the inferior vena cava, at a distance of 20 mm from the junction with the right atrium (Figure 1A). Via the right femoral approach, the membrane was perforated using a Brockenbrough transseptal needle and a Mullins sheath (Cook Europe, Bjaeverskov, Denmark), under fluoroscopic guidance in several views (Figure 1B). A small amount of contrast material was injected during the process of penetrating the membrane to assure proper needle angle. After perforating the occlusion, normal positioning in the junction of the right atrium was confirmed with contrast injection. Using a right femoral approach, a 290-mm PT Graphix intermediate angioplasty guidewire (Boston Scientific

Correspondence: Dr. A. Sánchez Recalde.
Unidad Médico-Quirúrgica de Cardiología. Hospital Universitario La Paz.
P.º de la Castellana, 261. 28046 Madrid. España.
E-mail: recalde@secardiologia.es

Received February 18, 2004.
Accepted for publication May 5, 2004.

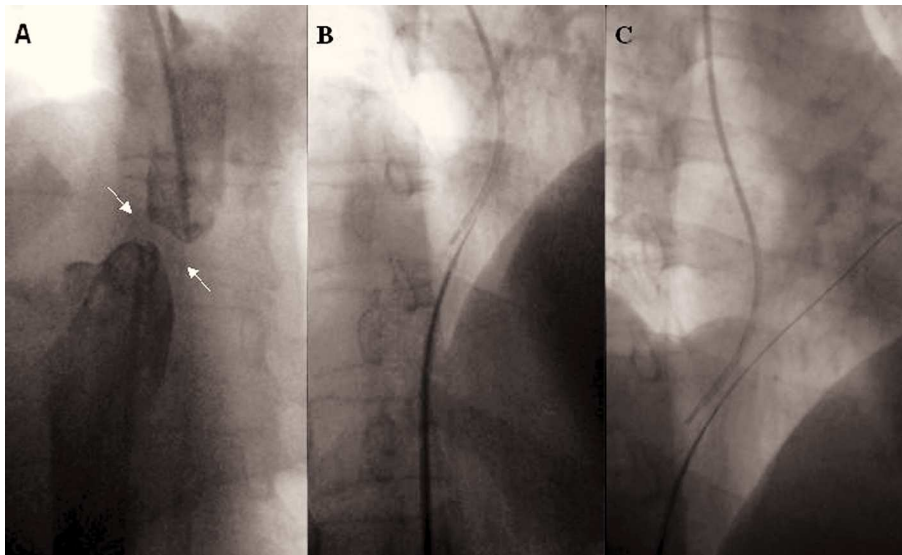


Fig. 1. A: angiographic image of membranous occlusion. B: the occlusion is perforated with a Brockenbrough needle. C: angioplasty guidewire in the right atrium through the needle.

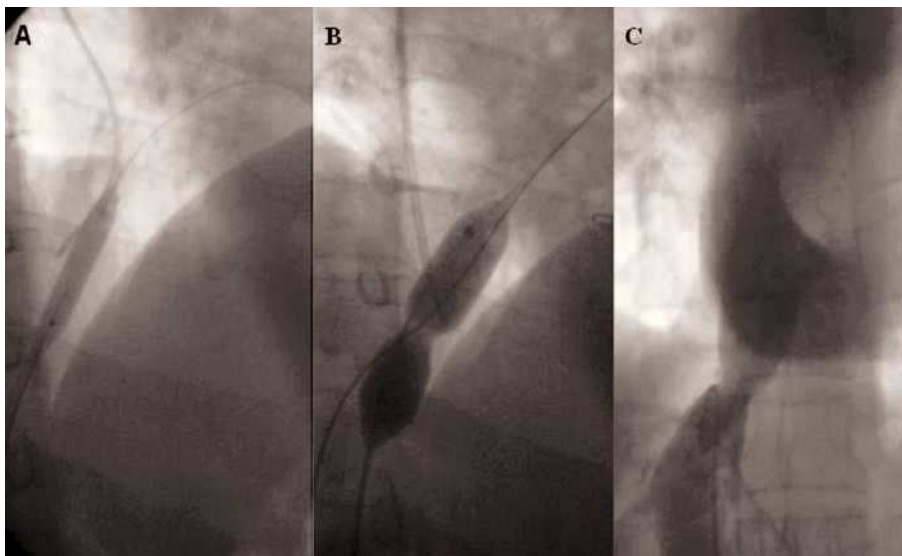


Fig. 2. A: dilation with angioplasty balloon. B: the narrowing is visible during dilation with a Multitrack valvuloplasty balloon. C: recanalization of the inferior vena cava after balloon dilation.

Scimed, Plymouth, Minnesota, USA) was inserted through the Brockenbrough needle and the needle was withdrawn (Figure 1C). Subsequently, balloons of increasing caliber were advanced through the Mullins sheath over the guidewire, dilating the obstruction in successive steps. We first used a 3-mm CrossSail balloon (Guidant Corp., Temecula, California, USA) and then a 5-mm Diamondback balloon (InSitu Technologies, Inver Grove Heights, Minnesota, USA) (Figure 2A). Finally, a 16-mm Bonhoeffer Multitrack balloon for mitral valvuloplasty (NuMED, Hopkinton, New York, USA) was inflated (Figure 2B) and the formation of a new lumen became visible (Figure 2C). Nevertheless, there was significant elastic recoil, leaving a residual peak-to-peak gradient of 10 mm Hg. Given the outcome, the decision was made to perform a second procedure with stent implantation. In this second

procedure, again via the right femoral vein, predilation with a Maxi LD balloon (20×80 mm) (Cordis, Johnson & Johnson, Miami, Florida, USA) was performed at 4 atm, and a 40-mm length Palmaz stent (P 4014) (Cordis, Johnson & Johnson, Miami, Florida, USA) was inserted over the balloon catheter. The procedure was successful and there was no residual gradient (Figure 3A and B). Right-sided follow-up catheterization at 12 months after stent implantation showed no significant restenosis (Figure 3C). At the follow-up over two years later, the patient remains asymptomatic and has not required diuretic treatment.

DISCUSSION

The angiographic study in this patient showed complete membranous occlusion of the inferior vena

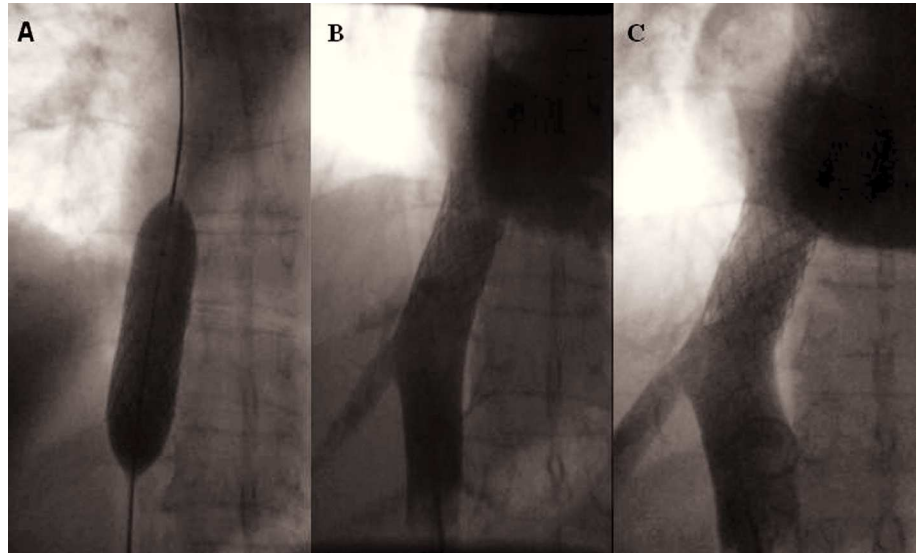


Fig. 3. A: process of stent implantation in the vena cava. B: immediate final result of stent placement. C: follow-up angiography at 12 months.

cava. Formerly, this type of occlusion was considered to have a congenital origin. However, based on findings obtained with new imaging techniques and histological studies, it has been postulated that the membranes are the sequelae of a thrombotic process.² This theory is logical in the patient presented, with a hypercoagulable state and primary antiphospholipid syndrome.

Treatment for Budd-Chiari syndrome varies according to the etiology and level of the obstruction. In cases of complete or segmental occlusion of the inferior vena cava, the use of percutaneous revascularization procedures is increasingly more common, whereas surgery is reserved for cases that cannot be resolved percutaneously.^{3,4} The procedure can be performed safely under fluoroscopic guidance in several views to assure proper angling of the needle as it perforates the membrane.⁵ Balloon angioplasty offers good initial results, although the rate of restenosis varies from 3% to 48% according to the series.^{5,6} As compared to results with the balloon, stenting improves the long-term outcome as it reduces the incidence of restenosis.⁷

In conclusion, percutaneous revascularization for complete vena cava occlusion in a patient with Budd-Chiari syndrome was a safe procedure that proved long-term effectiveness.

ACKNOWLEDGEMENT

We are grateful to Dr. Fernando Olías de la Cruz for his invaluable help in preparing the photographic images.

REFERENCES

1. Menon KV, Shah V, Kamath PS. The Budd-Chiari syndrome. *N Engl J Med* 2004;350:578-85.
2. Sevenet F, Deramond H, Hadengue A, Casadevall N, Delamarre J, Capron JP. Membranous obstruction of the inferior vena cava associated with a myeloproliferative disorder: a clue to membrane formation? *Gastroenterology* 1989;97:1019-21.
3. Yang XL, Cheng TO, Chen CR. Successful treatment by percutaneous balloon angioplasty of Budd-Chiari syndrome caused by membranous obstruction of inferior vena cava: 8-year follow-up study. *J Am Coll Cardiol* 1996;28:1720-4.
4. Benito Bartolomé F, González García A, Oliver Ruiz JM. Dilatación intraluminal de la estenosis de la vena cava inferior tras corrección del síndrome de la cimitarra en el adulto. *Rev Esp Cardiol* 2002;55:190-2.
5. Xu K, He FX, Zhang HG, Zhang XT, Han MJ, Wang CR, et al. Budd-Chiari syndrome caused by obstruction of the hepatic inferior vena cava: immediate and 2-year treatment results of transluminal angioplasty and metallic stent placement. *Cardiovasc Intervent Radiol* 1996;19:32-6.
6. Wu T, Wang L, Xiao Q, Wang B, Li S, Li X, et al. Percutaneous balloon angioplasty of inferior vena cava in Budd-Chiari syndrome-R1. *Int J Cardiol* 2002;83:175-8.
7. Zhang CQ, Fu LN, Xu L, Zhang GQ, Jia T, Liu JY, et al. Long-term effect of stent placement in 115 patients with Budd-Chiari syndrome. *World J Gastroenterol* 2003;9:2587-91.