

Axillary Artery Cannulation With a Dacron Graft for Surgery of the Aortic Arch and Ascending Aorta

José I. Sáez de Ibarra, Fernando Enríquez, Rubén F. Tarrío, Ramón Barril, and Oriol Bonnin

Servicio de Cirugía Cardíaca, Palma de Mallorca, Balearic Islands, Spain

Cannulation of the axillary artery is one possible means of establishing cardiopulmonary bypass during surgery of the ascending aorta and aortic arch. Use of a Dacron graft for cannulation has a number of advantages. In this article, we report our experience with this technique in 7 consecutive patients in whom we performed an ascending aorta replacement. The associated procedures involved were aortic root reconstruction using David's procedure in 2 patients, the Bentall procedure in 1, the hemi-arch technique in 2, the complete arch and elephant trunk technique in 1, aortic valve repair in 1, and Valsalva sinus reconstruction in one. Circulatory arrest with antegrade cerebral perfusion was carried out in 3 cases. There was no in-hospital mortality, and there were no vascular or infectious complications related to axillary access. One patient presented with transient paresthesia of the brachial plexus. In all cases, cardiopulmonary bypass flow was adequate.

Key words: Aortic surgery. Cerebral perfusion. Cardiopulmonary bypass.

Canulación axilar mediante prótesis de Dacron en cirugía del arco y la aorta ascendente

La canulación de las arterias axilares para instaurar la circulación extracorpórea es una alternativa en la cirugía del arco y la aorta ascendente. Su canulación mediante una prótesis de Dacron presenta ciertas ventajas. En el presente trabajo comunicamos nuestra experiencia con esta técnica en 7 pacientes consecutivos. En todos se realizó un recambio de la aorta ascendente. Se asociaron los siguientes procedimientos: reconstrucción de la raíz aórtica según técnica de David en 2 pacientes, intervención de Bentall en uno, hemiarco en dos, arco completo y trompa de elefante en uno, resuspensión de velos aórticos en uno y reconstrucción de senos de Valsalva en uno. Se realizó parada circulatoria con perfusión anterógrada en 3 casos.

La mortalidad hospitalaria fue nula. No hubo complicaciones vasculares ni infecciosas del abordaje axilar. Un paciente presentó una parestesia transitoria por afección del plexo braquial. El flujo de la circulación extracorpórea fue adecuado en todos los casos.

Palabras clave: Cirugía aorta. Perfusión cerebral. Circulación extracorpórea.

INTRODUCTION

Peripheral cannulation is used in patients requiring cardiopulmonary bypass before a sternotomy, or when cannulation of the ascending aorta is not advisable, for example in cases of type A aortic dissections, or in patients with aneurysms of the ascending aorta, and aortic arch.

The femoral artery and vein have been the preferred cannulation sites for cardiopulmonary bypass in such

cases, although alternative sites such as the axillary arteries, and supraaortic branches have been proposed.¹⁻⁴ Right axillary artery cannulation permits antegrade perfusion without manipulation of the ascending aorta, and thereby facilitates procedures in the distal ascending aorta and aortic arch. The aim of the present study was to evaluate the efficacy of using a graft during cannulation of the right axillary artery.

METHODS

This was a descriptive study using prospective data from the Hospital Universitario Son Dureta cardiac surgery database. All clinical records were reviewed manually.

In 2004, 8 consecutive patients received cannulation of the right axillary artery using a Dacron graft. In 1

Correspondence: Dr. J.I. Sáez de Ibarra.
Hospital Universitario Son Dureta. Servicio de Cirugía Cardíaca.
Andrea Doria, 55. 07014 Palma de Mallorca. Baleares. España.
E-mail: jisaezdeibarra@hsd.es

Received November 22, 2005.
Accepted for publication June 13, 2006.

patient, it was decided not to use the technique because of the presence of a retrosophageal subclavian artery. Patient characteristics are shown in Table.

Surgical Approach to the Axillary Artery

Blood pressure in both arms, and core temperature were invasively monitored. The patient was placed in a supine position with arms parallel to each side. Before the median sternotomy, a horizontal skin incision of about 7 cm was made, 2 cm below the median lateral portion of the right clavicle (deltopectoral crest). The pectoral major and minor muscles were dissected, and the vascular and nerve bundle exposed. The axillary artery was identified, dissected, and isolated from the axillary vein and the branches of the brachial plexus (Figure). After heparinization (3 mg/kg), the axillary artery was occluded using vascular clamps. A longitudinal arteriotomy was performed and the 8-mm Dacron graft anastomosed. The clamps were removed and hemostasis verified. The Dacron graft was cut 6 cm from the anastomosis and a 20-F straight arterial cannula was introduced via the graft. Alternatively, the arterial line can be connected to the graft directly with the aid of an adapter. The Dacron tube was fixed to an arterial line and venous cannulation, or median sternotomy was performed as appropriate. On completion of the intervention, and after heparin reversal, the graft was occluded and sectioned using vascular clips before surgical reconstruction.

Cardiopulmonary Bypass

An adequate pump flow rate was achieved, with flows over 4 L/min in all cases (mean body surface: 2 m²). No

cases of high pressure in the arterial line were observed. Cooling was performed in all patients until a core temperature of 32°C was reached. In patients with circulatory arrest (n=3), core temperature decreased to 26°C-28°C and antegrade cerebral perfusion (ACP) was performed at 18°C (10 mL/kg, 1-1.5 L/min) via the axillary artery through the clamped brachiocephalic trunk. Mean cardiopulmonary bypass and ischemia times were 150 (19) and 96 (13) mins, respectively. Mean ACP time was 35 (1) min. The mean duration of circulatory arrest with moderate hypothermia was 15 (1) min.

RESULTS

Complications of axillary cannulation

One patient presented with transient paresthesia of the brachial plexus which recovered in 48 h without sequelae. There were no cases of traumatic dissection of the axillary artery. There were no right arm vascular complications and no local complications at the scar site.

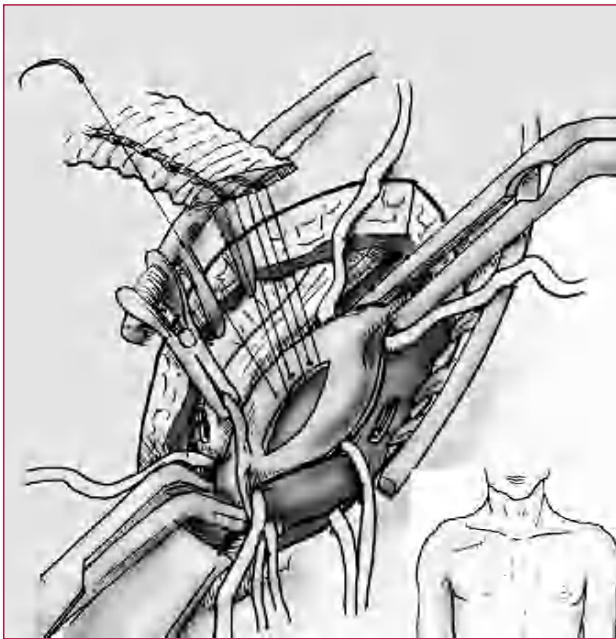
Overall Results

There was no in-hospital mortality. No re-operations due to bleeding were required and there were no neurological complications. In 57% of patients, extubation was performed within 24 h. The maximum mean creatine kinase MB isoenzyme (CK-MB) value for the series was 26 (12) mg/dL. Atrial fibrillation was the most frequent cardiovascular complication (50%). One patient presented with a non-Q wave acute myocardial infarction (patient with preoperative type

TABLE 1. Operative Characteristics of Patients With Cannulation of the Right Axillary Artery*

	Age	Sex	Indication for Surgery	Intervention	Motive for AAC	Circulatory Arrest
1	62	Male	Urgent. AAD	AA substitution with supracoronary tube + sinus reconstruction	AA cannulation impossible	No
2	56	Male	Urgent. AAD	AA substitution and conservation of aortic valve using David's procedure	AA cannulation impossible	No
3	53	Female	Urgent dissected AIH	Substitution AA and hemiarch with supracoronary tube + correction of sinotubular junction	AA cannulation impossible	Yes
4	47	Male	Elective. Aneurysm aortic arch	AA replacement + aortic arch + elephant trunk	Aortic arch surgery	Yes
5	72	Male	Emergency. Tamponade. AAD	AA substitution with supracoronary tube + valve resuspension	AA cannulation impossible	No
6	38	Female	Urgent. AAD	Bentall procedure + hemiarch	AA cannulation impossible	Yes
7	48	Male	Urgent. AAD	AA substitution and conservation of aortic valve using David's procedure	AA cannulation impossible	No

*AA indicates ascending aorta; AAC, axillary artery cannulation; AAD, A type aortic dissection; AIH, aortic intramural hematoma.



Detail of Dacron graft suture on axillary artery. The brachial plexus can be observed to the left of the graft and the axillary vein to the right. The diagram shows details of the site of skin incision.

A aortic dissection and occlusion of the right coronary artery).

One patient presented a temporary disturbance in renal function but recovered completely. Renal function in 2 patients with preoperative anuria was satisfactory after the intervention. A transfusion was performed in 85% of patients. The mean length of hospital stay was 10 (6) days (range, 8-22).

Post-Operative Ultrasonography

Transthoracic echocardiography was performed in all patients on discharge. The aortic valve was conserved in 5 of the 6 patients with aortic insufficiency (in 2 interventions using David's procedure, in 1 aortic valve repair, 1 Valsalva sinus reconstruction, and 1 correction of the sinotubular junction). None of the patients had greater than grade 1 positive aortic insufficiency.

COMMENTS

Cannulation of the femoral vessels during surgery for aortic dissection and aneurysms of the aortic arch carries a risk of poor perfusion and retrograde thrombotic embolism and atherosclerotic plaque in patients with extensive atherosclerotic disease of the thoracic, and abdominal aorta.³ In order to reduce these complications, other sites have been proposed for central and peripheral cannulation including the ascending aorta, the supraaortic trunks, and the axillary arteries.^{1,2,4-6}

Cannulation of the right axillary artery during aortic arch procedures facilitates exposure during surgery and

provides certain advantages when antegrade cerebral perfusion is used.²

The axillary artery is generally more fragile than the femoral artery and direct cannulation can therefore be traumatic. The most common complications of direct cannulation are dissection of, or damage to the artery. Likewise, closing the arteriotomy after direct cannulation is difficult and can lead to stenosis. Other complications have been described, such as the compartment syndrome in the arm being perfused or the impossibility of achieving adequate flow during cardiopulmonary bypass.⁷ The risk of these complications can be reduced by using a side graft.^{3,6,7}

In the present series, there were no vascular complications arising from the cannulation of the axillary artery when using the Dacron graft. Closure of the arteriotomy was quick and easy.

In the present series, there were no cases of poor perfusion. In 3 cases, the technique allowed a circulatory arrest with moderate hypothermia to be performed safely, with a surgical field that was free of cannulae. In 1 case, the technique had to be abandoned due to retroesophageal right subclavian artery. This anomaly and the presence of significant atherosclerotic lesions can be detected during preoperative radiological diagnostics and by systematically determining whether asymmetry in pulse and blood pressure between the right and left arms is present.

In other series, complications arising from direct cannulation of the axillary artery have been observed in 4%-8% of patients.^{3,6,8,9} Schachner et al⁶ reported a 9% decrease in arterial damage and dissection, and a 4% reduction in cannulation problems when a Dacron graft was used in axillary artery cannulation.⁶

Based on these results, the axillary artery is our preferred site for cannulation in surgery involving dissection of the aorta and ascending arch. With the aid of a Dacron graft, a lateral anastomosis is performed to facilitate cannulation and establish cardiopulmonary bypass. It also allows for rapid improvisation of circulatory arrest and maintenance of antegrade cerebral perfusion via the brachiocephalic trunk. The technique can also be used when there is significant calcification and atheromatosis in the distal ascending aorta which could complicate cannulation of the artery.

Given the excellent outcomes in this series in terms of mortality and neurological complications, we recommend using this technique in patients requiring surgery of the distal ascending aorta and aortic arch.

REFERENCES

1. Kazui T, Washiyama N, Muhammad BAH, Terada H, Yamashita K, Takinami M. Improved results of atherosclerotic arch aneurysm operations with a refined technique. *J Thorac Cardiovasc Surg.* 2001;121:491-9.

- Mazzola A, Gregorini R, Villani C, di Eusanio M. Antegrade cerebral perfusion by axillary artery and left carotid artery inflow at moderate hypothermia. *Eur J Cardiothorac Surg.* 2002; 21:930-1.
- Sabik JF, Neme H, Lytle BW, Blackstone EH, Gillinov AM, Rajeswaran J, et al. Cannulation of the axillary artery with a side graft reduces morbidity. *Ann Thorac Surg.* 2004;77:1315-20.
- Westaby S, Katsumata T. Proximal aortic perfusion for complex arch and descending aortic disease. *J Thorac Cardiovasc Surg.* 1998;115:162-7.
- di Eusanio M, Quarti A, Pierri MD, di Eusanio G. Cannulation of the brachiocephalic trunk during surgery of the thoracic aorta: a simplified technique for antegrade cerebral perfusion. *Eur J Cardiothorac Surg.* 2004;26:831-3.
- Schachner T, Nagiller J, Zimmer A, Laufer G, Bonatti J. Technical problems and complications of axillary artery cannulation. *Eur J Cardiothorac Surg.* 2005;27:634-7.
- Sinclair MC, Singer RL, Manley NJ, Montesano RM. Cannulation of the axillary artery for cardiopulmonary bypass: safeguards and pitfalls. *Ann Thorac Surg.* 2003;75:931-4.
- Strauch JT, Spielvogel D, Lauten A, Lansman SL, McMurtry K, Bodian CA, et al. Axillary artery cannulation: routine use in ascending aorta and aortic arch replacement. *Ann Thorac Surg.* 2004; 78:103-8.
- Neri E, Massetti M, Capannini G, Carone E, Tucci E, Diciolla F, et al. Axillary artery cannulation in type a aortic dissection operations. *J Thorac Cardiovasc Surg.* 1999;118:324-9.