

Original article

## Assessment of Silent Microembolism by Magnetic Resonance Imaging After Cardioversion in Atrial Fibrillation

María Vázquez,<sup>a,\*</sup> Eloísa Santos,<sup>b</sup> Iria Rodríguez,<sup>c</sup> Antonio Pato,<sup>c</sup> Manuel Vilar,<sup>a</sup> Juan C. Arias,<sup>a</sup> Rafael Fernández,<sup>a</sup> Isabel Costas,<sup>a</sup> Alejandro Ghioldi,<sup>a</sup> Marcelo Sanmartín,<sup>a</sup> and Francisco Tardáguila<sup>b</sup>

<sup>a</sup>Servicio de Cardiología, Hospital Povisa, Vigo, Pontevedra, Spain

<sup>b</sup>Servicio de Radiología, Hospital Povisa, Vigo, Pontevedra, Spain

<sup>c</sup>Servicio de Neurología, Hospital Povisa, Vigo, Pontevedra, Spain

Article history:

Received 9 May 2011

Accepted 17 August 2011

Available online 5 December 2011

Keywords:

Cerebral ischemia

Cardioversion

Atrial fibrillation

Palabras clave:

Isquemia cerebral

Cardioversión

Fibrilación auricular

### ABSTRACT

**Introduction and objectives:** To study electrical cardioversion in patients with atrial fibrillation as a potential cause of acute ischemic brain lesions.

**Methods:** We performed prospective analysis of 62 consecutive patients (62 [10] years, 16 female). All of them were anticoagulated for at least 3 weeks with an international normalized ratio of 2.69 (0.66). In all cases a magnetic resonance imaging of the brain was performed before and 24 h after the cardioversion, including diffusion-weighted sequences. A neurological exploration was also performed before and after the procedure, using the modified Ictus on the National Institute of Health Stroke Scale and the modified Rankin scale. Written informed consent was obtained in all cases.

**Results:** Of the 62 patients, 51 (85%) reverted to sinus rhythm. The neurological examination showed no changes after cardioversion. The pre-procedure magnetic resonance imaging showed microvascular disease in 35 (56%), including 2 patients with known cerebrovascular disease, and did not depict new clinically silent ischemic areas after cardioversion.

**Conclusions:** After electrical cardioversion no acute ischemic lesions in the brain nor alteration in the neurological scales were found. Nevertheless, in 35 patients (56%) with persistent atrial fibrillation, the magnetic resonance imaging showed clinically silent ischemic lesions.

© 2011 Sociedad Española de Cardiología. Published by Elsevier España, S.L. All rights reserved.

### Valoración mediante resonancia magnética cerebral de embolias clínicamente silentes en pacientes con fibrilación auricular sometidos a cardioversión eléctrica

### RESUMEN

**Introducción y objetivos:** Estudiar si la cardioversión eléctrica en pacientes con fibrilación auricular puede causar lesiones cerebrales isquémicas agudas clínicamente silentes.

**Métodos:** Se realizó un análisis prospectivo de 62 pacientes consecutivos (media de edad, 62 ± 10 años; 16 mujeres). Todos ellos fueron anticoagulados durante al menos 3 semanas con acenocumarol, manteniendo una media de razón internacional normalizada = 2,69 ± 0,66. En todos los casos se realizó una resonancia magnética cerebral antes y 24 h después de la cardioversión, incluidas las secuencias potenciadas en difusión. Se realizó también una exploración neurológica antes y después del procedimiento, utilizando las escalas de ictus *National Institute of Health Stroke Scale* y de Rankin modificada. Se obtuvo el consentimiento informado por escrito en todos los casos.

**Resultados:** De los 62 pacientes, en 51 (85%) se revirtió a ritmo sinusal. La exploración neurológica no mostró cambios después de la cardioversión. La resonancia magnética realizada antes del procedimiento mostró enfermedad de pequeño vaso en 35 pacientes (56%); de ellos, 2 presentaban enfermedad cerebrovascular previa conocida. La resonancia magnética tras la cardioversión no mostró nuevas áreas de isquemia en ningún caso.

**Conclusiones:** Después de la cardioversión, no encontramos cambios en la exploración neurológica ni áreas de isquemia aguda en la resonancia magnética de ningún paciente de nuestra serie. Sin embargo, en nuestro estudio, la resonancia magnética basal mostró lesiones isquémicas clínicamente silentes en 35 pacientes (56%) con fibrilación auricular persistente.

© 2011 Sociedad Española de Cardiología. Publicado por Elsevier España, S.L. Todos los derechos reservados.

\* Corresponding author: Servicio de Cardiología, Hospital Povisa, Salamanca 5, 36211 Vigo, Pontevedra, Spain.

E-mail address: macriscv@yahoo.es (M. Vázquez).

### Abbreviations

AF: atrial fibrillation  
 INR: international normalized ratio  
 MRI: magnetic resonance imaging  
 NIHSS: National Institute of Health Stroke Scale

## INTRODUCTION

Atrial fibrillation (AF) is the most common arrhythmia in clinical practice, with a high prevalence in the elderly population.<sup>1</sup> The risk of thromboembolic events is 5 times greater in patients with AF than in those in sinus rhythm.<sup>2,3</sup> Several studies<sup>4</sup> have shown decreased cognitive capacity in patients with AF, with an increased risk of dementia. It is thought that this cognitive decline may be due to silent brain infarcts.<sup>5</sup>

One of the primary objectives of treatment for AF is to maintain sinus rhythm. The most effective strategy in these cases is direct-current cardioversion.<sup>6</sup> If the procedure is programmed, the patient should have been receiving anticoagulation therapy for at least 3 weeks, given the high risk of embolic events if such prophylaxis is not administered.<sup>7,8</sup> Even so, thromboembolic events occur during the procedure in up to 1% according to some series.<sup>9</sup> Moreover, we do not know whether small silent brain infarcts may be occurring.<sup>10</sup>

Currently, the new diffusion-weighted imaging sequences in brain magnetic resonance imaging (MRI)<sup>11</sup> can show small areas of cerebral ischemia in the initial hours after an embolic event, even when asymptomatic.

The aim of this study was to assess new-onset silent ischemic lesions after programmed direct-current cardioversion using diffusion-weighted sequences in brain MRI.

## METHODS

We studied 62 patients (16 women) with persistent AF who were scheduled for direct-current cardioversion to revert to sinus rhythm.

The exclusion criteria were clinical instability, carrier of a pacemaker or any metal prosthesis that contraindicated MRI, gadolinium allergy, and claustrophobia.

The study was reviewed and approved by the hospital research ethics committee.

All patients received information in writing about the study and completed an informed consent form.

### Study Protocol

All patients received acenocoumarol at least 4 weeks before the procedure to maintain an international normalized ratio (INR) between 2 and 3. All participants signed an informed consent in accordance with the requirements of the hospital ethics committee.

All patients underwent a complete neurological examination according to the modified Rankin scale and the National Institute of Health Stroke Scale (NIHSS), as well as a brain MRI 1 to 2 h before cardioversion. The neurological test and brain MRI were repeated 24 h later. The results of the neurological examination before and after cardioversion were compared, as were MRI images before and after the procedure.

## Cardioversion Procedure

The study was performed in patients in a fasting state. All patients were sedated with propofol (1 mg/kg body weight). The scan was performed with the patient in the anterolateral position with an initial shock of 100 J, with QRS gating and a biphasic electrode. If AF persisted, a second shock of 200 J was applied. If arrhythmia continued, a shock of 270 J was applied.

## Magnetic Resonance Imaging

The MRI protocol included 2 studies, the first hours before direct-current cardioversion and the second 24 h after the procedure, using a 1.5 T system (1.5 T Intera; Philips Medical Systems). Standard sequences were used, including a sagittal T1 morphologic sequence, 2 axial T2-enhanced sequences and FLAIR (fluid-attenuated inversion recovery), a coronal T2-enhanced sequence, and a diffusion-weighted sequence. The latter used a repetition time of 3100, an echo time of 90 ms, and a field of view of 230 mm. In total, 22 5-mm slices were recorded with 1 mm between slices. A b value of 0 and 1000 was used, and in all cases the apparent diffusion coefficients were mapped. Both the diffusion images and apparent diffusion coefficient maps were assessed for all patients (Fig. 1) and the results of these 2 studies performed 24 h apart were compared. In doubtful cases, diffusion-weighted images were quantified and compared with the opposite side.

The MRI scans were interpreted independently by 2 neuro-radiologists with 8 and 4 years experience, respectively, in the field of neuroradiology.

## Statistical Analysis

This was a descriptive study. Qualitative variables were expressed as mean (standard deviation) and discontinuous ones as percentages.

The Student *t* test was used to assess for significant differences between continuous variables, while the  $\chi^2$  test was used for discontinuous ones.

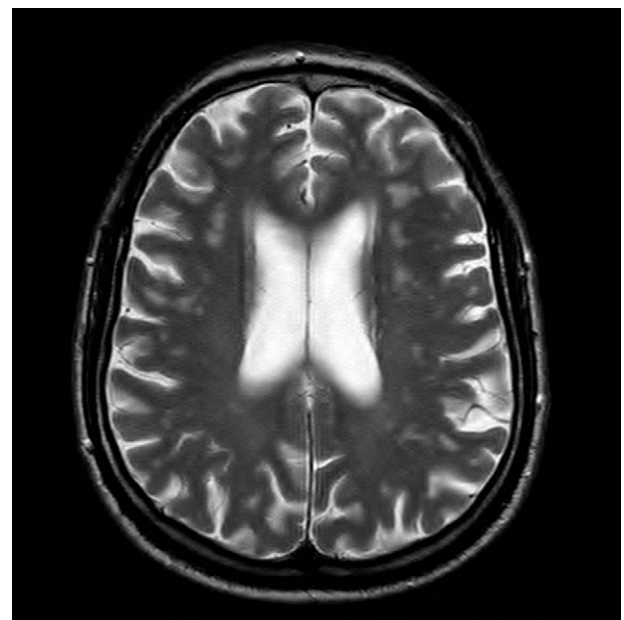


Figure 1. Apparent diffusion coefficient map.

**Table 1**  
Patient Characteristics

Age, years	62±10
Women	16 (26)
Smoking habit	7 (11.3)
Hypertension	39 (63)
Diabetes mellitus	5 (8)
Prior embolism	3 (4.8)
Valve disease	5 (8)
Ischemia	6 (9.6)
More than 1 year in AF	15 (24)
Left atrium	45±5.5
LVEF, %	58±8
Heart failure	10 (16)
Peripheral vascular disease	2 (3.2)
Permanent OAC	29 (46.8)
Aspirin	22 (35.5)
Clopidogrel	2 (3.2)

AF, atrial fibrillation; LVEF, left ventricular ejection fraction; OAC, oral anti-coagulation.

Data are expressed as mean±standard deviation or no. (%).

**Table 2**  
Patient Distribution According to the CHADS<sub>2</sub> Classification

Score	Patients, no. (%)
0	20 (32.3)
1	25 (40.3)
2	11 (17.7)
3	5 (8)
4	1 (1.6)
Total	62 (100)

## RESULTS

Patient characteristics are summarized in Table 1. The distribution according to CHADS<sub>2</sub> and CHA<sub>2</sub>DS<sub>2</sub>VASc categories<sup>18</sup> is summarized in Tables 2 and 3, respectively.

Of the 62 patients, 51 (85%) reverted to sinus rhythm. The neurological examination was normal in 61 patients, with a score of 0 in the NIHSS and modified Rankin scale, both before and after cardioversion. One patient with a known history of resected meningioma had a score of 4 on the NIHSS and 0 on the modified Rankin scale, with no changes observed in the examination after cardioversion.

**Table 3**  
Patient Distribution According to the CHA<sub>2</sub>DS<sub>2</sub>VASc Classification

Score	Patients, no. (%)
0	10 (16)
1	18 (29)
2	15 (24.2)
3	11 (17.7)
4	5 (9.1)
5	2 (3.2)
6	1 (1.6)
Total	62

**Table 4**  
Clinical Characteristics According to Findings in Baseline Magnetic Resonance Imaging

Clinical characteristics	MRI with ischemia	MRI without ischemia	P
Age, years	65±9	58±11	.015
Men	27 (77.1)	19 (73.1)	
Women	8 (22.9)	7 (26.9)	.770
Smoking habit	4 (11.4)	3 (11.5)	1
HT	22 (62.9)	16 (61.5)	1
Valve disease	4 (11.4)	1 (3.8)	.382
Diabetes mellitus	3 (8.6)	2 (7.7)	1
Dyslipidemia	10 (46.2)	12 (46.2)	.186
Prior embolism	1 (2.9)	2 (7.7)	.570
Ischemia	4 (11.4)	2 (7.7)	1
Permanent OAC	17 (48.6)	11 (42.3)	.795
Vascular disease	1 (3.8)	1 (2.9)	1
Heart failure	7 (20)	3 (11.5)	.494
Aspirin	15 (42.9)	7 (26.9)	.282
Clopidogrel	2 (5.7)	0	.503

HT, hypertension; MRI, magnetic resonance imaging; OAC, oral anticoagulation. Data are expressed as mean±standard deviation or no. (%).

In the MRI prior to cardioversion, microvascular ischemic lesions were found in 35 (56.4%) patients. However, no new MRI lesions were observed after cardioversion.

In a secondary analysis, we investigated whether there was a relationship between ischemic lesions found in the baseline MRI and the clinical characteristics of the patients (Table 4).

The only statistically significant risk factor for ischemic lesions in the baseline MRI was age ( $P<.05$ ).

## DISCUSSION

In the present study, there were no clinically observable ischemic events after direct-current cardioversion. We ensured that the patients had an INR between 2 and 3 for at least 3 weeks. There were no new clinically silent brain lesions in the MRI.

Diffusion-weighted MRI has been shown to be every effective for detecting silent ischemia in other situations in which the risk of cardiac embolism is high.<sup>12,13</sup>

In different series of patients undergoing pulmonary vein ablation, silent infarcts were observed in between 1% and 2%,<sup>14,15</sup> although in these cases the procedure was more aggressive and oral anticoagulation was withdrawn a few days earlier to be replaced by low-molecular-weight heparins.

Some cases have been reported of patients undergoing direct-current cardioversion in which silent ischemia is detected by intracranial Doppler measurements.<sup>16</sup> It is, however, a less sensitive and specific technique. The new diffusion-weighted brain sequences allow detection of acute ischemia in a 48-h period with a high diagnostic yield.

The high percentage of patients who have microvascular disease in the MRI prior to the procedure is noteworthy. The aim of this study was not to correlate these lesions with associated risk factors, such as age, hypertension, diabetes mellitus, structural heart disease, or peripheral artery disease. However, these findings prompted us to investigate whether we should consider anti-coagulation when there are ischemic lesions in the MRI in patients with a low risk of symptomatic embolism according to clinical criteria.<sup>10,17,18</sup>

The present study has several limitations. The first is the low number of patients. In addition, the fact that it was a single-center study means that we cannot extrapolate to the general population.

Our findings might also be somewhat unreliable given that we did not record any events. However, the study is a reflection of clinical practice when undertaking a scheduled direct-current cardioversion.

However, our results do suggest that we can avoid thromboembolic events, including clinically silent ones, by being strict with oral anticoagulation before undertaking a scheduled electric cardioversion.

## CONCLUSIONS

In our series, we did not detect acute ischemic lesions after direct-current cardioversion through brain MRI diffusion sequences in a series of 62 patients with persistent AF who were receiving anticoagulation therapy. Appropriate anticoagulation therapy for at least 4 weeks, with an INR between 2 and 3, allows direct-current cardioversion to be performed safely. In addition, we observed that a high percentage of patients with AF had microvascular disease, although without any clinical repercussions.

## CONFLICTS OF INTEREST

None declared.

## REFERENCES

- Kannel WB, Abbot RD, Savage D, McNamora PM. Epidemiologic features of chronic atrial fibrillation. The Framingham study. *N Engl J Med.* 1982;306:1018–22.
- Wolf PA, Abbot R, Kannel WB. Atrial fibrillation as an independent risk factor for stroke: the Framingham Study. *Stroke.* 1991;22:983–8.
- Predictors of thromboembolism in atrial fibrillation I: clinical features of patients at risk. Stroke prevention in atrial fibrillation investigators. *Ann Intern Med.* 1992;116:1–5.
- Ott A, Breteler M, De Bruyne M, Van Harskamp F, Grobbee DE, Hofman A. Atrial fibrillation and dementia in a population-based study: the Rotterdam Study. *Stroke.* 1997;28:316–21.
- Vermeer S, Prins ND, Den Heijer T, Hofman A, Koustaal PJ, Breteler MM. Silent brain infarcts and the risk of dementia and cognitive decline. *N Engl J Med.* 2003;348:1215–22.
- Lown B, Perloff MG, Kaidbey S, Abe T, Harken DE. Cardioversion of atrial fibrillation. A report on the treatment of 65 episodes in 50 patients. *N Engl J Med.* 1963;269:325–31.
- Gallagher MM, Hennessey BJ, Edvardsson N. Embolic complications of direct current cardioversion of atrial arrhythmias: association with low intensity of anticoagulation at the time of cardioversion. *J Am Coll Cardiol.* 2002;4:926–33.
- Kinch JW, Davidoff R. Prevention of embolic events after cardioversion of atrial fibrillation. Current and evolving strategies. *Arch Intern Med.* 1995;55:1353–60.
- Bejerkelund CJ, Orning OM. Efficacy of anticoagulant therapy in preventing embolism related D.C. electrical cardioversion in atrial fibrillation. *Am J Cardiol.* 1969;23:208–15.
- Cullinane M, Wainwright R, Brown A, Monaghan M, Hugh S. Asymptomatic embolization in subjects with atrial fibrillation not taking anticoagulants. A prospective study. *Stroke.* 1998;29:1810–5.
- Kang DW, Lattimore SU, Latour LL, Warach S. Silent ischemic lesion recurrence of magnetic resonance imaging predictors subsequent clinical vascular events. *Arch Neurol.* 2006;63:1730–3.
- Barh A, Remonda L, Lövbled K, Schnoth G, Seiler RW. Silent cerebral ischemia detected by diffusion-weighted MRI after carotid endarterectomy. *Stroke.* 2000;31:1824–8.
- Haman M, Gomes S, Oppenheim C, Morello R, Sabatier R. Cerebral microembolism during cardiac catheterization and risk of acute brain injury. A prospective diffusion-weighted magnetic resonance imaging study. *Stroke.* 2006;37:2035–8.
- Gaitia F, Caponi D, Pianelli M, Scaglioni M, Toso E, Cesarani F, et al. Radiofrequency catheter ablation of atrial fibrillation: a cause of silent thromboembolism? Magnetic resonance imaging assessment of cerebral thromboembolism in patients undergoing ablation of atrial fibrillation. *Circulation.* 2010;122:1667–73.
- Schröckel JW, Lickfett L, Lewalter T, Mittman-Braun E, Selbach S, Strach K, et al. Incidence and predictors of silent cerebral embolism during pulmonary vein catheter ablation for atrial fibrillation. *Europace.* 2010;12:52–7.
- Kay R, Chung HK, Wong KS, Li H, Wong A, Woo KS, et al. Transcranial Doppler evaluation of microembolism immediately after direct-current cardioversion for atrial fibrillation. *Am J Cardiol.* 1999;93:7–8.
- Camm AJ, Kirchhof P, Lick GYH, Schotten U, Savelieva I, Ernst S, et al. Guidelines of the management of atrial fibrillation. *Eur Heart J.* 2010;31:2369–429.
- Gersh BJ, Freedman JE, Granger CB. Tratamiento antiagregante plaquetario y anticoagulante para la prevención del ictus en pacientes con fibrilación auricular no valvular: nuevos avances basados en la evidencia. *Rev Esp Cardiol.* 2011;64:260–8.