

Angina Related to 5-Fluorouracil

Juan Luján, Fernando García de Burgos, Alejandro Jordán, Miguel García, Fernando Reyes and María D. Espinosa

Sección de Cardiología. Servicio de Medicina Interna. Hospital General Universitario de Elche.

Treatment with 5-fluorouracil is common in oncological patients. Side effects on bone marrow, skin, and mucous membranes have been reported. Cardiotoxicity, which is less predictable, can be life-threatening. Manifestations include angina, arrhythmias, infarction, heart failure and cardiogenic shock. The toxic mechanisms that might be involved have been much discussed but have not yet been clearly established. Current evidence supports the possibility of a metabolic effect in common with the cascade secondary to ischemia due to coronary disease. Based on a case report, we discuss the usual clinical presentation, treatment and prognosis. Finally we make recommendations for managing patients being treated with 5-fluorouracil.

Key words: *Unstable angina fluorouracil. Drug toxicity. Vasospasm.*

Full English text available at: www.revespcardiol.org

INTRODUCTION

5-fluorouracil (5FU), an anti-neoplastic agent known since 1957, is a synthetic analogue of pyrimidine that degrades cellularly into various nucleotides that potently and competitively inhibit thymidilate synthesis, causing a depletion in thymidilate that capable of halting nuclear transcription and ribosome translocation. The cytotoxic effects are also mediated by the incorporation of fluorodexiuridine triphosphate into DNA and 5FU into RNA.

5FU has been used above all for the treatment of gastrointestinal adenocarcinoma, breast and prostate cancer, and squamous cell cancer of the head and neck and in gynecological tumors.

Correspondence: Dr. J. Luján.
Sección de Cardiología. Hospital General Universitario de Elche.
Camino de la Almazara, 11. 03203 Elche. España.
E-mail: garcia_ferde@gva.es

Recibido el 22 de junio de 2001.
Aceptado para su publicación el 27 de noviembre de 2001.

Angina en relación con 5-fluorouracilo

El tratamiento con 5-fluorouracilo en pacientes oncológicos es una práctica habitual. Son conocidos sus efectos secundarios sobre la médula ósea, la piel y las mucosas. Menos predecible es su cardiotoxicidad, que puede llegar a ser letal. Sus manifestaciones incluyen angina, arritmias, infarto, insuficiencia cardíaca y shock cardiogénico. Se ha especulado mucho sobre los mecanismos implicados en esta toxicidad, que aún no han sido definitivamente establecidos. Con los datos actuales, todo apunta a un efecto metabólico común con el desencadenado en la isquemia cardíaca por enfermedad coronaria. Comentamos, a partir de un caso, la presentación clínica habitual, el tratamiento y el pronóstico. Finalmente, hacemos unas recomendaciones prácticas para aplicar en los pacientes que vayan a seguir tratamiento con 5-fluorouracilo.

Palabras clave: *Angina inestable. Fluorouracilo. Toxicidad por fármacos. Vasoespasmo.*

The cardiotoxicity of some of the components used for treatment of patients with cancer is known: doxorubicin, with ultra structural changes related to accumulated doses; cyclophosphamide, which causes cardiac damage at high doses, and, infrequently, in cisplatin and radiation, but with possible synergy with other agents.

The cardiotoxicity of 5FU has been described as angina, with or without changes on electrocardiogram (ECG), acute myocardial infarction, induction or worsening of ventricular and supraventricular arrhythmias, and potentially reversible myocardial depression, analogous to that observed with anthracyclines. Nevertheless, its cardiac side-effects are less well known by clinicians than its effects on the mucous membranes, the skin, and the osseous medulla. We present a case in which the possible mechanisms of toxicity can be discussed, and practical conclusions reached.

CLINICAL CASE

The patient was a 69-year-old man whose only

ABBREVIATIONS

5FU: 5-fluorouracil.
ECG: electrocardiogram.

known significant clinical history was the diagnosis 3 months previously of stage IV sigma adenocarcinoma, with infiltration of the bladder and retro peritoneum, and metastases to the liver and upper right kidney. Resection and permanent colostomy were performed, and treatment with cisplatin and 5FU were recommended by the oncology service. The patient received an initial dose and another dose 6 days later. Approximately 12 hours after receiving the latter dose, the patient was taken to the emergency room due to an episode of oppressive non-radiating chest pain, suggestive of angina, with dyspnea and vegetative signs. On physical examination, neither murmurs nor rubs were detected on cardiac auscultation, nor were signs of ventricular dysfunction. There were no significant changes on chest x-ray. On ECG a sinus rhythm was observed, with greater than 1 mm depression of the ST segment in V5-V6 and less markedly I, II, and V3-V4, and sharp symmetric T-waves in the same locations (Figure 1).

The patient was treated with sublingual nitroglycerine, with instantaneous clinical improvement, normalization of the ST segment, and complete inversion of the T-waves in the same areas (Figure 2). The patient later suffered a new episode of chest pain with the same ECG changes that was completely controlled by

the administration of intravenous nitroglycerine. The patient was admitted with a diagnosis of unstable angina, and with the usual treatment regimen. Ordinary analysis did not reveal significant changes on hemogram, hydroelectric equilibrium tests, liver or kidney function tests, or markers for myocardial lesion.

With the suspected diagnosis of vasospastic angina, given the electrical changes and the patient's behavior, coronary angiography was performed, and revealed a coronary tree without lesions, with normal volume and segment contractility on ventriculography.

Under medical treatment with nitroglycerine and calcium antagonists, the patient remained asymptomatic. The ECG only showed persistent non-specific repolarization changes. 5FU therapy was discontinued, and the patient received a new cisplatin dose days after the coronary angiography without incident. He continued to be asymptomatic from a cardiological point of view, until his death 7 months later secondary to cancer.

DISCUSSION

The bibliography includes reviews of clinical cases that have been collected, as well as the few prospective studies designed to study this type of cardiotoxicity.^{4,5} Its incidence varies, according to the various series, from 1.2% to 18%.⁴

Little is known about the individual variability in the pharmacokinetics of 5FU in host and tumor cells. Eighty percent of the degradation is hepatic and 20% is eliminated by the kidneys. Gastrointestinal mucous membranes, the skin, the cerebellum, and the myocardium capture it selectively. The predominant side-effects are diarrhea, stomatitis, nausea and vomiting,

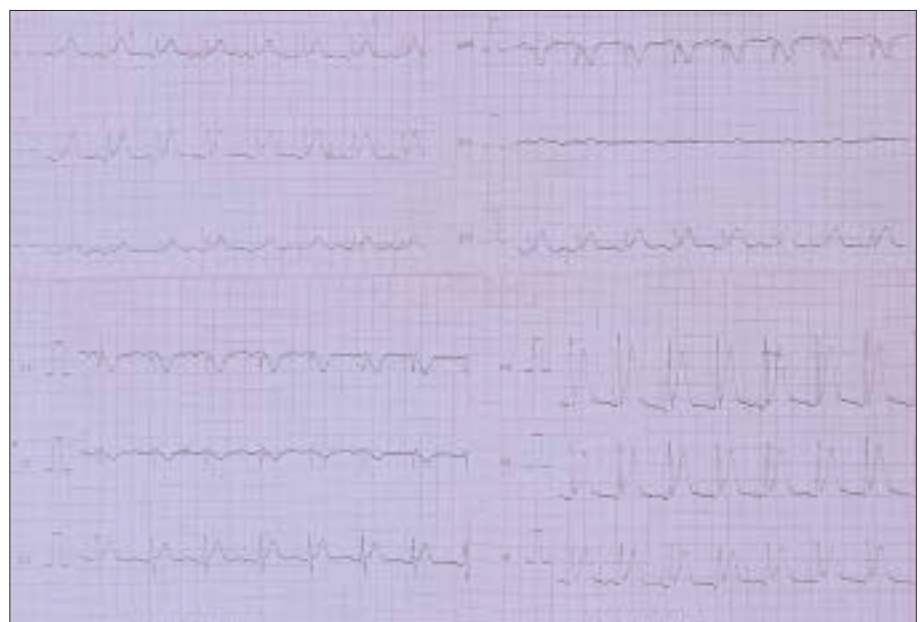


Fig. 1. Electrocardiogram performed during an episode of chest pain, with signs suggestive of acute ischemia (depression of the ST segment).

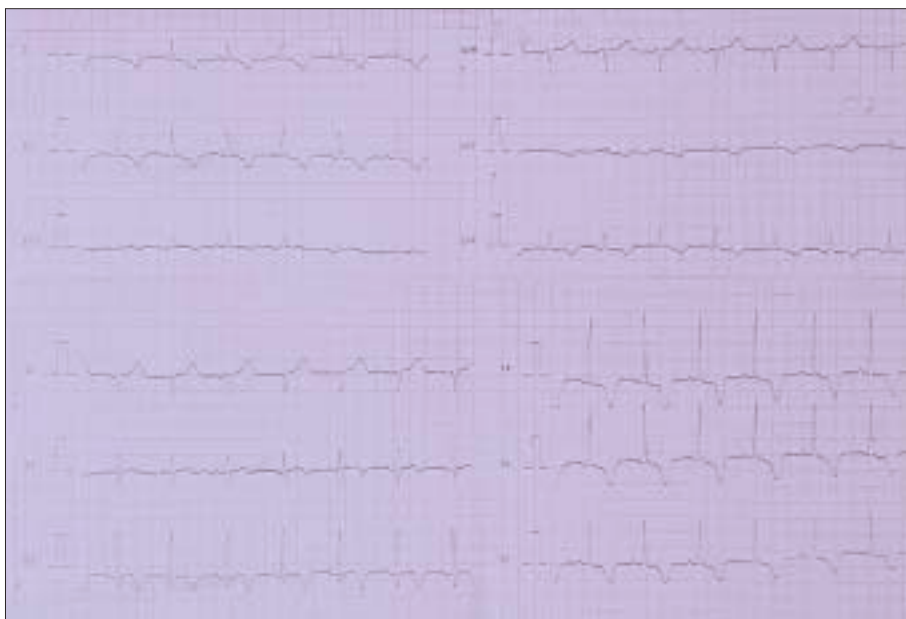

Fig. 2. Electrocardiogram of the same patient after treatment.

leukopenia, alopecia, and cerebella ataxia.

Clinical signs appear in the great majority of cases within the first 72 hours,⁴ and usually not later than within the first 3 cycles, which excludes the need for an accumulated dose. They tend to consist of angina with ischemic changes on ECG; they also appear with a normal ECG, and with less frequency as an infarct, arrhythmia, cardiac insufficiency, or cardiogenic shock. The symptoms are highly reproducible if treatment is stopped. In general, myocardial enzymes are unchanged. When echocardiography is performed, overall, or at times regional, dysfunction of the left ventricle can be detected that resolves in approximately 1 week, as does the myocardial daze. Coronary angiography and endomyocardial biopsy tend to be normal.

The physiopathology has yet to be unequivocally determined, if indeed a single cause exists. The temporal relationship and the clinical presentation strongly suggest an ischemic component or a common method of action with ischemia. The absence of coronary epicardial disease supports the hypothesis of vasospasm, and, in fact, aortic ring vasoconstriction in rabbits has been demonstrated after the administration of 5FU that is reversible with nitroglycerine administration. Nevertheless, there are no conclusive results with regard to the occurrence of vasospasm when 5FU is administered during coronary angiography in patients with cardiotoxicity.⁶ There has been discussion regarding damage of the endothelial cells with maximum effect during the first 3 days of treatment, coinciding with the clinical course, and of the added potential formation of a reversible thrombus. An ischemic toxic effect on cell metabolism has been suggested, mediated by the entrance into the Krebs cycle

of its derivate, fluoroacetate. Metabolic changes have been described, with a decline in ATP values and citrate accumulation, in Guinea pigs with ischemia and electrocardiographic changes, without changes in the myocardial flow. In fact, there may be characteristics in common with fluoroacetate intoxication. Nevertheless, this does not explain the non-diffuse damage and the lack of effect on the non-cardiac organs. The 5FU dose, individual differences in metabolism, and myocardial susceptibility also may intervene in the process.

It seems clear that vasospasm by itself would not explain all the possible changes, or the histopathological findings of patchy or diffuse damage observed in patients who die of cardiogenic shock. There must be cell failure (mitochondrial, nucleic acid metabolism, structural proteins, ionic channels) that causes myocardial dysfunction, without evidence of necrosis and similar to a post-ischemic myocardial daze.

In some series⁷ a greater rate of cardiotoxicity has been noted in patients with a history of heart disease, but these results are controversial. The incidence of heart disease in the review of 134 cases compiled by Robyben et al¹ is not greater than that of the general population in the same age group, and does not offer conclusive data showing that a history of heart disease increases the risk of cardiotoxicity. No differences have been found between the incidence of cardiotoxicity in 5FU monotherapy and 5FU poly-therapy. As in the case we present, angina and nonspecific ECG changes have been described, as well as supraventricular arrhythmias with 5FU and cisplatin, but the latter alone is rarely associated with cardiotoxicity. A synergic effect cannot be excluded, nor can the possibility that cisplatin is associated with a greater volume over-

load or electrolytic changes.

In summary, the existence of distinct mechanisms and possible predisposing factors make it very difficult to identify those patients at greater risk for developing these side-effects. Broader studies are needed to identify these risk factors.

Usually, there is good response to treatment with nitroglycerine and calcium antagonists, but these have not been proven to be effective prophylactically. Nevertheless, this toxicity is a potentially lethal complication, with a mortality rate described as 2.2%,¹ generally by acute myocardial infarction or cardiogenic shock.

Given the widespread use of 5FU, it would seem prudent to recommend that a baseline ECG be performed, as well as echocardiography in patients with a history of heart disease. Initiating treatment in patients with a recent infarct, unstable angina, malignant arrhythmias, or severe cardiac insufficiency is not recommended. It is fundamental to note the appearance of cardiac symptoms or ECG changes, so that treatment can be interrupted immediately, thus avoiding more severe complications. In the case of cardiotoxicity, treatment is basically symptomatic, with nitrogly-

cerine, calcium antagonists, and even ECA inhibitors. 5FU must not be restarted as it is highly probable that the symptoms will recur; treatment with raltitrexed is recommended instead.

REFERENCES

1. Robben NC, Pippas AW, Moore JO. The syndrome of 5-fluorouracil cardiotoxicity. An elusive cardiopathy. *Cancer* 1993;71:493-507.
2. Leone B, Rabinovich M, Ferrari CR, Boyer J, Rosso H, Strauss E. Cardiotoxicity as result of 5-fluorouracil therapy. *Tumori* 1985; 71:55-7.
3. Weidmann B, Jansen W, Heider A, Niederle N. 5-Fluorouracil cardiotoxicity with left ventricular dysfunction after different dosing regimens. *Am J Cardiol* 1995;75:194-5.
4. Becker K, Erckenbrecht JF, Häussinger D, Frieling T. Cardiotoxicity of the antiproliferative compound fluorouracil. *Drugs* 1999;57:475-84.
5. De Forni M, Malet-Martino MC, Jaillais P, Shubinski RE, Bachand JM, Lemaire L. Cardiotoxicity of high-dose continuous infusion fluorouracil: a prospective clinical study. *J Clin Oncol* 1992;10:1795-801.
6. Freeman NJ, Costanza ME. 5-fluorouracil-associated cardiotoxicity. *Cancer* 1988;61:36-45.
7. Labianca R, Beretta G, Clerici M, Frascini P, Luporini G. Cardiac toxicity of 5-fluorouracil: a study on 1,083 patients. *Tumori* 1982;68:505-10.