

## Image in cardiology

## An Unusual Case of Single Coronary Artery

## Un caso excepcional de arteria coronaria única

Sandra Mayordomo,\* Carolina Granda, and Leire Unzué

Servicio de Cardiología, Hospital Universitario 12 de Octubre, Madrid, Spain

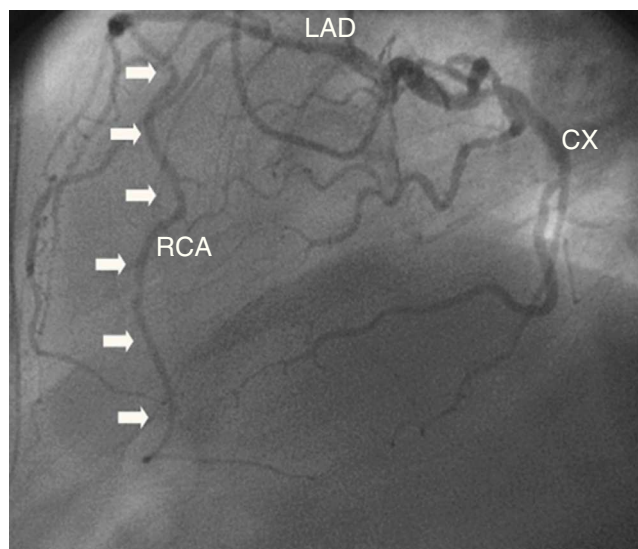


Figure 1.

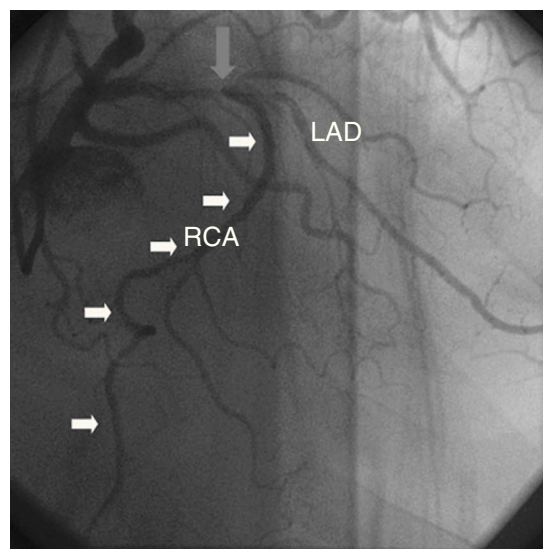


Figure 2.

An 81-year-old man with a history of hypertension, dyslipidemia, and diabetes consulted for progressive angina. Ergometry findings indicated a poor prognosis. Coronary angiography showed a severe lesion in the dominant circumflex artery (CX) at the bifurcation with the obtuse marginal artery. A severe calcified lesion was seen in the middle portion of the left anterior descending artery (LAD) at the bifurcation with an anomalous artery that ran anterior to the right ventricular outflow tract and reached the coronary sulcus, where it continued in the normal course of the right coronary artery (RCA) (Figs. 1 and 2). Angiography showed agenesis of the right coronary ostium. Myocardial revascularization surgery was undertaken.

Anomalous coronary arteries are seen in 0.3% to 1.3% of coronary angiography studies. Single coronary artery is uncommon (0.0024%-0.066%). Origin of the RCA from the LAD is extremely rare. Only 8 cases of RCA arising from the middle LAD have been described, and this is the first published case in Spain. Single coronary artery does not usually have clinical repercussions, although it can present with angina or sudden death. An association with an increase in arteriosclerotic disease has been hypothesized.

Computed tomography angiography is an aid to the diagnosis of coronary anomalies. It is not absolutely necessary if management is clarified by angiography. In patients older than 30 years with ischemic symptoms, the treatment is similar to that used in other patients because of the low risk of sudden death. In young patients with an interarterial course, a more aggressive management is recommended, and surgical treatment can be considered.

\* Corresponding author:

E-mail address: [sandrini@gmail.com](mailto:sandrini@gmail.com) (S. Mayordomo).

Available online 15 July 2013