

Acute Compartment Syndrome of the Hand After Transradial Catheterization



Síndrome compartimental agudo de la mano tras un cateterismo transradial

To the Editor,

The routine use of transradial access in cardiology is due to its proven advantages over femoral access. Although hemostasis is easily achieved, bleeding can occur through the puncture site (PS). This bleeding can lead to hematomas and, on rare occasions, acute compartment syndrome (ACS), which can become serious without early and appropriate treatment. Here, we present and discuss an exceptional case of ACS of the hand (ACSh) that was resolved for the first time using a conservative approach involving a quick and simple maneuver.

Preoperative coronary angiography was performed in an 82-year-old woman with severe aortic stenosis via a right transradial approach using a valved introducer (5-Fr Glidesheath, Terumo) and heparin 5000 IU. The procedure was completed without complications and with compression of the PS with an elastic bandage. Swelling immediately appeared, which progressed rapidly to marked edema of the hand. Attempts were made to compress the PS, first with a pneumatic device and then with manual compression. After 5 minutes of unsuccessful compression attempts, the patient was in intense pain, requiring opioids, and had paresthesia in the affected hand. Physical examination revealed a large tension hematoma and cyanotic and ecchymotic fingers. The hand was flexed and very painful upon movement/extension (Figure 1A). All of these signs and symptoms are compatible with the diagnosis of ACSh.

The radial artery was then compressed 3–5 cm proximal to the PS (in an area without hematoma). Although the compression stopped the progression, the tension edema persisted and there was no improvement in symptoms. Thus, we empirically decided to use a scalpel to extend the initial PS, which produced a gush of nonpulsatile blood (Figure 1B and Figure 1C). After 2 minutes of drainage, the signs and symptoms progressively disappeared. The procedure was finalized by compressing the PS (now hematoma-free) with a pneumatic device. The clinical course in the next 3 weeks was excellent and without sequelae (Figure 2).

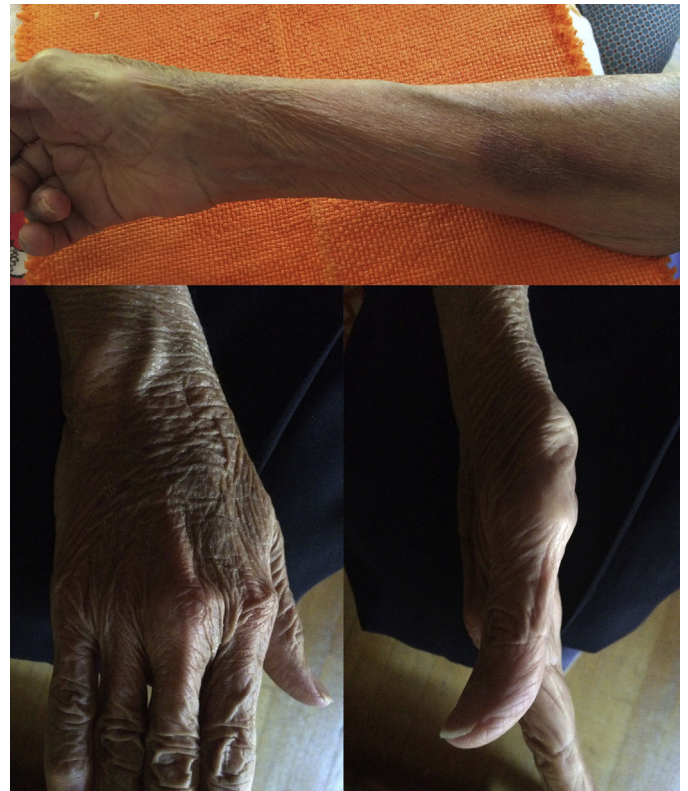

Figure 2. Hand and forearm 3 weeks later; virtual symptom resolution (except for mild persistent ecchymosis in the forearm).

Acute compartment syndrome, produced by increased pressure in 1 or more fascial spaces, leads to decreased perfusion pressure and muscular and nerve ischemia. Its rapid diagnosis is vital because, without early treatment, it becomes a serious condition with important functional repercussions. There are several “classic” causes, with trauma being the most frequent.

Diagnosis is clinical (involving the “5Ps”: pain, pulselessness, pallor, paresthesia, and paralysis). The most common and characteristic symptom is intense pain. This pain is refractory to analgesia and frequently disproportionate to the visible injuries.

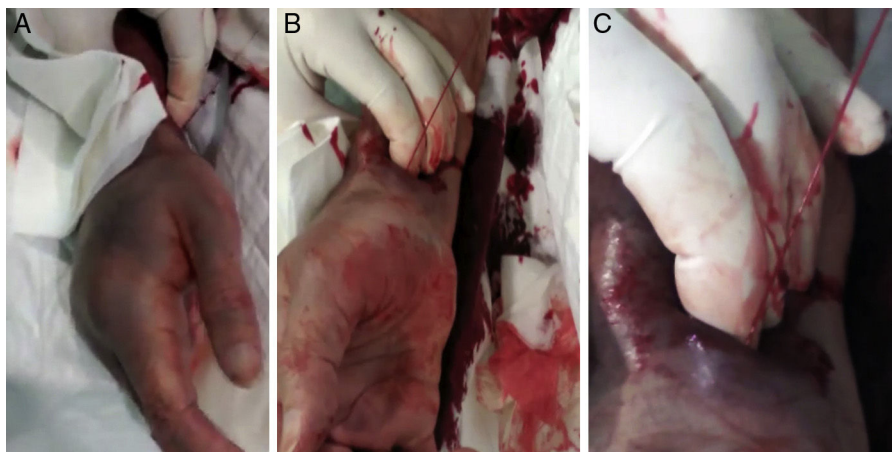


Figure 1. A: right hand with signs of compartment syndrome. B and C: photograph taken 2 minutes after manual compression of the radial artery showing a gush of nonpulsatile blood (because it was from the hematoma and not the radial artery, which would be pulsatile).

The other symptoms and signs are not always present and their absence does not rule out ACS. Edema is an early symptom and the paresthesia and paralysis are delayed signs (caused by nerve ischemia). In ACS, the hand is characteristically in flexion, due to the intense pain caused by movement/extension of the fingers. The definitive treatment is fasciotomy, which is almost always performed. When the clinical findings are insufficient or to decide when to perform a fasciotomy, direct measurement of the intracompartmental pressure is an option.¹

The development of ACS after transradial catheterization has been described in the forearm. This part of the upper limb contains 3 compartments (anterior, posterior, and mobile wad); ACS affects the anterior compartment (also known as the volar compartment) because the radial artery passes through this compartment. This particular ACS has an incidence of about 0.125%. It is generally caused by perforation (by guidewires or catheters) of the small arteries of the forearm proximal to the PS, and the bleeding occurs at a distant site from the PS. In contrast to the “classic” ACS, if it is identified at an early stage, ACS of the forearm can usually be resolved using an elastic tensor bandage or by inflating a pressure cuff on the affected forearm.² In refractory cases, a fasciotomy should be performed. Early treatment failure can lead to a chronic deformity called Volkmann ischemic contracture.

An ACS after a transradial procedure is highly unusual. In our institute, this is the first case among 17 965 transradial procedures, giving an incidence of 0.005%. The hand has 11 compartments (thenar, hypothenar, central palmar, adductor, and 7 interosseous spaces). The “classic” treatment recommends removal of the compression bandages and a fasciotomy. In the only other previously described case of ACS, spontaneous laceration of the hand occurred and the ACS was resolved with drainage and surgical debridement.³ Our exceptional case of ACS after transradial catheterization was easily resolved by expanding the PS hole using a scalpel, with no need for surgery. We believed that the ACS was caused not by artery rupture, but by inadequate initial compression and the subsequent hematoma, which further complicated the compression. We also considered that, due to the

small initial transradial PS, the blood was unable to drain to the exterior and preferentially drained into the hand. Accordingly, use of a scalpel to simply expand the puncture hole in the epidermis and the subcutaneous cellular tissue would facilitate blood outflow and complete resolution of the ACS. Due to its simplicity, when ACS develops after transradial catheterization, this maneuver should first be attempted before fasciotomy is performed.

Josebe Goirigolzarri-Artaza,^a Raquel Casado-Álvarez,^b Jaime Benítez-Peyrat,^a Ebrey León-Aliz,^a Javier Goicolea,^a and Arturo García-Touchard^{a,*}

^aUnidad de Cardiología Intervencionista, Hospital Universitario Puerta de Hierro, Majadahonda, Madrid, Spain

^bServicio de Cardiología, Hospital Universitario Getafe, Getafe, Madrid, Spain

* Corresponding author:

E-mail address: agtouchard@gmail.com (A. García-Touchard).

Available online 10 February 2017

REFERENCES

- Codding JL, Vosbikian MM, Ilyas AM. Acute compartment syndrome of the hand. *J Hand Surg Am.* 2015;40:1213–1216.
- Sanmartín M, Cuevas D, Goicolea J, Ruiz-Salmerón R, Gómez M, Argibay V. Vascular complications associated with radial artery access for cardiac catheterization. *Rev Esp Cardiol.* 2004;57:581–584.
- Song L, Yang SW, Zhou YJ. Severe dorsal hand laceration secondary to compartment syndrome following transradial coronary intervention. *J Interv Cardiol.* 2015;28:612–613.

<http://dx.doi.org/10.1016/j.rec.2016.11.026>

1885-5857/

© 2016 Sociedad Española de Cardiología. Published by Elsevier España, S.L.U. All rights reserved.

Prevalence of Neuroendocrine Tumors in Patients With Cyanotic Congenital Heart Disease



Prevalencia de tumores neuroendocrinos en pacientes con cardiopatías congénitas cianóticas

To the Editor,

Pheochromocytoma and paraganglioma are neuroendocrine tumors (NETs) that produce catecholamines derived from neural crest cells, localized in the adrenal medulla (90%) or in extra-adrenal chromaffin tissue (10%). Their prevalence is between 0.2% and 0.6% in hypertensive adults, 5% in adrenal incidentalomas, and 0.05% to 0.1% in autopsy series.¹ Although they usually present as isolated tumors, they can be associated with hereditary syndromes such as multiple endocrine neoplasms, neurofibromatosis, or von Hippel Lindau syndrome. Furthermore, there have been case reports and small series highlighting the association between cyanotic congenital heart defects (CCHD) and NETs.² Recently, Opatowsky et al.³ reported an increased risk of NETs in patients with CCHD in a multicenter study in which the role of chronic hypoxia in association with genetic

susceptibility was proposed as the underlying pathogenic mechanism for these tumors.

A retrospective analysis was performed of 3311 adults with congenital heart defects, 173 with CCHD, and 33 with Eisenmenger syndrome in a national referral center for adult congenital heart defects. The median length of follow-up was 25 years (range, 10.5 years). All patients with suspected NET under follow-up in the endocrinology department underwent computed tomography and metaiodobenzylguanidine scintigraphy, with monitoring of catecholamines in urine.

A total of 8 NETs were identified in 7 patients with CCHD (4.6%) (Table 1). Overall, 48.8% were men and the median age was 40.0 years (range, 19.0–47.0 years). All patients had active cyanosis at the time of diagnosis (mean, 36.0 ± 11.3 years), including 1 patient with Fontan circulation with venovenous collaterals. The mean baseline arterial oxygen saturation was 83.4% ± 6.3%, mean hemoglobin was 18.1 ± 2.0 g/dL, and mean hematocrit was 66.5% ± 7.3%. Three patients had Eisenmenger syndrome (9.1% of all patients had this syndrome). On analysis of all patients with congenital heart defects, including those with noncyanotic disease, 1 additional NET was identified in a patient with partial anomalous pulmonary venous drainage (0.2% overall).