

Ablation of Familial Atrial Fibrillation. Favorable Long-Term Outcome

To the Editor:

We present the case of a 39-year-old man with no risk factors for cardiovascular disease. He had a 6-year history of paroxysmal atrial flutter and fibrillation, documented by electrocardiogram and Holter. He complained of daily episodes of rapid, irregular palpitation. There was no radiographic or echographic evidence of structural myocardial abnormalities. Other members of the family (a grandmother, his father, a brother and at least two uncles) had a history of atrial fibrillation that had begun at an early age (Figure). All of them had been diagnosed as having "isolated" atrial fibrillation. Our patient had been treated unsuccessfully with diltiazem, flecainide, and propafenone. An electrophysiological study revealed the presence of typical atrial flutter. Radiofrequency ablation was performed and the flutter was interrupted by bidirectional isthmus block. Treatment was continued with flecainide at a dose of 100 mg/12 h. During follow-up, multiple episodes of paroxysmal atrial fibrillation were detected, and ablation of the pulmonary veins was indicated. This procedure was performed with the patient in sinus rhythm. Two electrode catheters were introduced via right femoral vein and a third via subclavian vein. Double transeptal catheterization was successfully performed, and pulmonary vein potentials were recorded using a 4-mm Mariner ablation catheter (Medtronic) and a Lasso catheter (Cordis). The 4 pulmonary veins were isolated (power setting: 50 W, 65°C) and the left isthmus was ablated, although abnormal potentials were detected only in the left superior pul-

monary vein. After a 30-month postablation follow-up period during which he received no antiarrhythmic therapy, the patient did not experience palpitations and the Holter recording was normal.

Ablation of atrial fibrillation constitutes a real and effective therapeutic option in many patients with very frequent episodes that are refractory to antiarrhythmic therapy.¹⁻³ Familial atrial fibrillation is a heterogeneous genetic disease that is an object of continuous research.^{4,5} Until now, the prospects for the treatment of these patients were limited. We report the case of a patient with atrial fibrillation that could have an autosomic dominant pattern of inheritance or could be the outcome of both parents having a recessive genetic disorder. Its penetrance is apparently high. Associated heart disease or precipitating factors were not encountered. Brugada et al⁴ reported several cases of familial atrial fibrillation and identified the gene responsible for this disorder on chromosome 10, although it is assumed that there are probably a number of genetic abnormalities involved.⁴ In a certain proportion of patients with atrial fibrillation, we were unable to identify the cardiac disorder or its causes. Many of these patients may present either a hereditary or a de novo genetic abnormality. Catheter ablation for atrial fibrillation is progressively becoming accepted as an effective technique in the treatment of refractory patients.⁶ The keys to selecting the patient and the appropriate technique remain to be determined, as is the degree of efficacy in familial cases. The isolation of the pulmonary vein orifices makes it possible to eliminate the arrhythmogenic activity that triggers or perpetuates the arrhythmia without eliminating other possible foci. In our patient, we detected abnormal potentials only in the left superior pulmonary vein, although, given the characteristics of the case, we opted for the isolation of all 4 pulmonary veins and an additional line for left

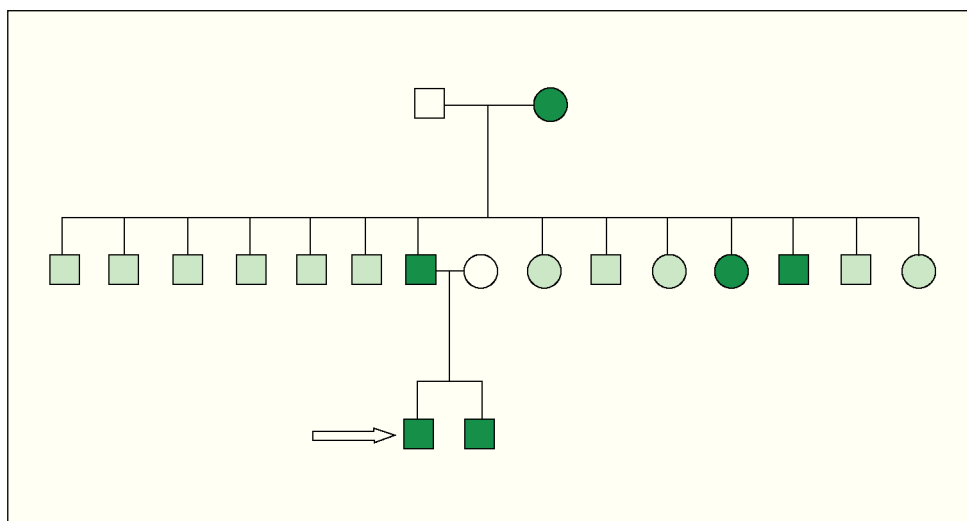


Figure. Family tree of the patient (who is indicated by the arrow). Square indicates man; circle, woman; darkened symbols, patient with atrial fibrillation; blank symbols, asymptomatic patient with no documented atrial fibrillation; shaded symbols, indeterminate.

isthmus block (between left inferior pulmonary vein and the mitral ring).

In conclusion, catheter ablation is a safe and effective technique for the treatment of atrial fibrillation that may also be successfully employed in patients with familial atrial fibrillation.

Antonio Hernández Madrid,
Gerardo Moreno, and Concepción Moro

Servicio de Cardiología, Unidad de Arritmias,
Hospital Ramón y Cajal, Departamento de Medicina,
Universidad de Alcalá, Madrid, Spain.

REFERENCES

1. Haissaguerre M, Jais P, Shah DC, Takahashi A, Hocini M, Quiniou G, et al. Spontaneous initiation of atrial fibrillation by ectopic beats originating in the pulmonary veins. *N Engl J Med.* 1998; 339:659-66.
2. Silva RM, Mont L, Berruezo A, Fosch X, Wayar L, Alvarenga N, et al. Ablación con radiofrecuencia en el tratamiento de la fibrilación auricular focal usando mapeo circunferencial y desconexión segmentaria de las venas pulmonares. *Rev Esp Cardiol.* 2003;56: 361-7.
3. Villacastín JP. Ablación percutánea de la fibrilación auricular: Buenas perspectivas. *Rev Esp Cardiol.* 2003;56:331-2.
4. Brugada R, Tapscott T, Czernuszewicz GZ, Marian AJ, Iglesias A, Mont L, et al. Identification of a genetic locus for familial atrial fibrillation. *N Engl J Med.* 1997;336:905-11.
5. Darbar D, Herron KJ, Ballew JD, Jahangir A, Gersh BJ, Shen WK, et al. Familial atrial fibrillation is a genetically heterogeneous disorder. *J Am Coll Cardiol.* 2003;41:2185-92.
6. Pappone C, Rosanio S, Oreto G, Tocchi M, Gugliotta F, Vicedomini G, et al. Circumferential radiofrequency ablation of pulmonary vein ostia: a new anatomic approach for curing atrial fibrillation. *Circulation.* 2000;102:2619-28.