

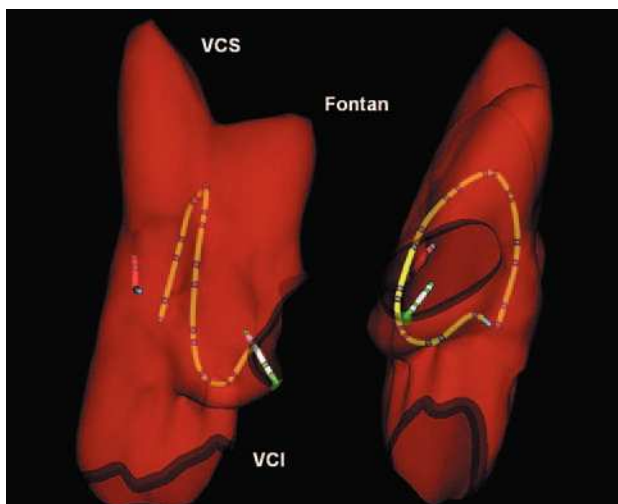Figure 1.

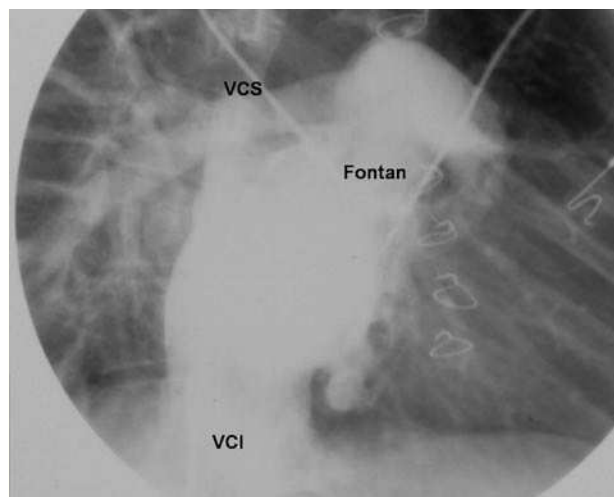


Figure 2.

Ablation Guided by Digital Anatomic Reconstruction (NavX[®])

A 26-year-old patient with tricuspid atresia that was repaired surgically using the Fontan procedure (atrial-to-pulmonary artery anastomosis and proximal closure of the pulmonary artery) was referred to investigate documented episodes of paroxysmal atrial flutter. During the electrophysiological study a reproducible, typical counterclockwise atrial flutter through the subeustachian isthmus was induced. Anatomical reconstruction of the right atrium (RA) was performed with the non-fluoroscopic NavX[®] navigation system (Endocardial Solutions, St. Paul, Minnesota, USA) (Figure 1: left image, right anterior oblique view; right image, left anterior oblique view), which showed, simultaneously, a quadripolar catheter in the right auricular appendage (red), a duodecapolar catheter around the tricuspid annulus (yellow), and an ablation catheter in the subeustachian isthmus (white). This system creates a 3-dimensional model of the endocardial surface by detecting and joining the signals acquired with the catheters. The anatomic reconstruction of the RA, inferior

vena cava (IVC), superior vena cava (SVC), and the atrial-to-pulmonary artery anastomosis (Fontan) was validated with angiography in the right anterior oblique view (Figure 2). Radiofrequency ablation of the subeustachian isthmus was performed.

In recent years catheter ablation has become the definitive treatment for many anatomic substrates. The technique has been favored by the development of several non-fluoroscopic navigation systems that can provide 3-dimensional anatomic reconstructions, an especially useful feature for patients with complex anatomy. Our case illustrates the excellent correlation between the anatomical model obtained with the NavX[®] system and the angiographic image.

Mariana Gnoatto, Mauricio Abello,
and José L. Merino

Unidad de Arritmias y Electrofisiología Cardíaca,
UMQ de Cardiología, Hospital General Universitario La Paz,
Madrid, Spain.