

## Scientific letters

**Abdominal Aortic Dilatation During Pregnancy in Marfan Syndrome****Aneurisma de aorta abdominal en el síndrome de Marfan durante la gestación****To the Editor,**

We present the case of a 29-year-old pregnant woman with Marfan syndrome who presented an aortic root diameter of <45 mm at the start of gestation with no other abnormalities. She had been diagnosed of Marfan syndrome 2 years previously as a result of a family study.<sup>1</sup> The patient underwent a follow-up cardiologic examination before becoming pregnant. At that time, the aortic root diameter at the sinuses of Valsalva on transthoracic echocardiography was 43 mm (Fig. 1).

At week 30 of gestation, a dilatation of the abdominal aorta consistent with a thrombosed aneurysm was visualized on obstetric ultrasound. Magnetic resonance imaging confirmed the abdominal aortic aneurysm, which originated just below the superior mesenteric artery, continued to the aortic bifurcation, and had a maximum diameter of 58 mm and an associated parietal thrombus; there was no evidence of thoracic aorta dissection or dilatation (Fig. 2). On transthoracic echocardiography, the left ventricle showed no dilatation, systolic function was preserved (ejection fraction 55%), the right chambers were normal, and the ascending aorta was dilated at the sinus of Valsalva (45 mm).

During pregnancy, the patient received beta-blocker treatment with maximum doses of atenolol (50 mg/day), and blood pressure was well controlled (systolic arterial pressure <120 mmHg).

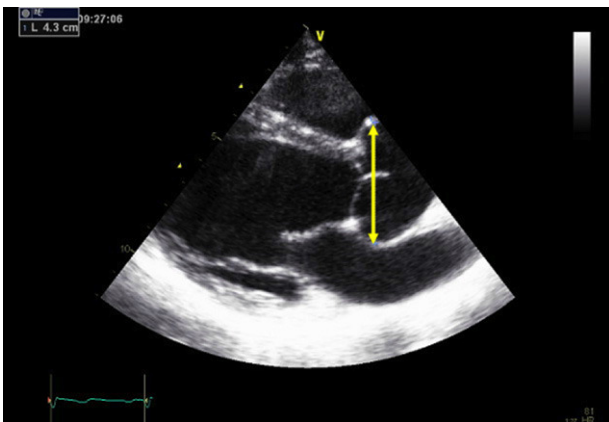
Following assessment by a multidisciplinary team (obstetricians, cardiologists, vascular surgeons, and anesthesiologists) to evaluate the maternal-fetal risk associated with this new finding, it was decided to finalize gestation at fetal maturity. Cesarean section was performed, and a baby boy was delivered (weight 1410 g, Apgar 7 at 1 min and 9 at 5 min, arterial pH 7.4, and venous pH 7.5). The patient was discharged at 7 days following the cesarean, and surgical repair of the abdominal aortic aneurysm was scheduled. One month later, the patient was hospitalized, the abdominal aortic aneurysm was resected, and a 20-mm Dacron

graft was placed from the distal thoracic aorta to the aortic bifurcation. During her intensive care unit stay, she required multiple transfusions, parenteral nutrition, and continuous renal replacement therapy due to acute kidney failure. At 17 days, the patient presented retrograde dissection of the thoracic aorta. Because of her critical situation, surgery was rejected as a treatment option in favor of emergency placement of a Cook endoprosthesis in the thoracic aorta. At 3 months posthospitalization, the patient was discharged in acceptable general condition.

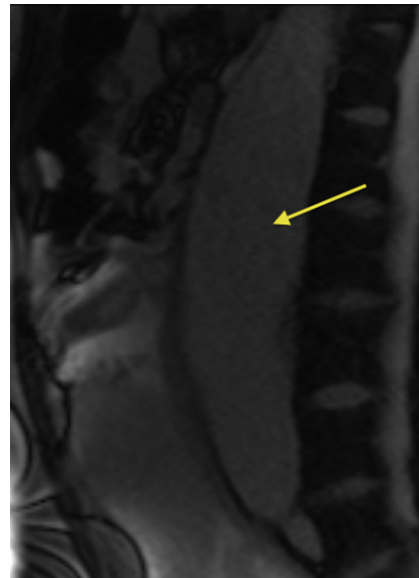
A large number of cardiac complications have been reported in pregnant women with Marfan syndrome, the most characteristic being thoracic aorta dissection.<sup>2</sup> Nonetheless, development of an abdominal aortic aneurysm during pregnancy in these patients has only been described previously as a finding during the puerperal period.<sup>3</sup>

Although most dissections occur in the ascending aorta, the descending thoracic aorta or abdominal aorta also can be affected. Aortic dissection can also occur in the low-risk group; that is, those without aortic dilatation.<sup>4</sup> Although that is rare, these women should be informed that a normal echocardiogram does not indicate an absence of risk. The family history of aortic dissection and rapid growth of the aortic diameter should be included in risk assessment.<sup>1</sup> It is essential to evaluate the entire aorta before and during pregnancy. Biomechanical assessment of aortic distensibility can help to identify patients without aortic dilatation who are at risk of dilatation or dissection.<sup>5</sup>

In pregnancies with a fetal gestational age of less than 28 weeks, the recommended treatment is aortic repair or medical treatment without finalizing pregnancy. When fetal gestational age is greater than 32 weeks, the recommended treatment is to finalize pregnancy by cesarian section with posterior aortic repair or medical treatment. In cases of gestational age between 28 and 32 weeks, the decision should be made on an individual basis by consensus between the mother and neonatologists.<sup>6</sup>



**Figure 1.** Transthoracic echocardiogram before pregnancy shows aortic root dilatation with a maximum diameter of 43 mm.



**Figure 2.** Sagittal magnetic resonance image (unenhanced white blood sequence) shows the abdominal aortic aneurysm (arrow).

This case illustrates the importance of performing abdominal ultrasound to monitor the size of the abdominal aorta, in particular after the second trimester of gestation when cardiac output increases. When any increase in the size of the aorta is documented on abdominal ultrasound, magnetic resonance is indicated to achieve a more precise assessment. The risk of aortic rupture or dissection secondary to development of a large dilatation or aneurysm is very high and implies a dismal prognosis.

All women with Marfan syndrome who wish to have a baby should be evaluated and counseled by a multidisciplinary team, primarily a cardiologist and obstetrician, with individualized determination of the associated risk.<sup>6</sup>

María Goya,<sup>a,\*</sup> María Alvarez,<sup>a</sup> Gisela Teixido-Tura,<sup>b</sup> Carme Merced,<sup>a</sup> Víctor Pineda,<sup>c</sup> and Arturo Evangelista<sup>b</sup>

<sup>a</sup>Unidad de Medicina Materno-Fetal, Servicio de Obstetricia, Hospital Universitari Vall d'Hebron, Barcelona, Spain

<sup>b</sup>Unidad de Marfan, Servicio de Cardiología, Hospital Universitari Vall d'Hebron, Barcelona, Spain

<sup>c</sup>Unidad de Resonancia Magnética, Servicio de Radiología, Hospital Universitari Vall d'Hebron, Barcelona, Spain

\*Corresponding author:

E-mail addresses: mariagoya@mac.com, mgoya@vhebron.net (M. Goya).

Available online 3 December 2011

## REFERENCES

1. Lebreiro A, Martins E, Almeida J, Pimenta S, Bernardes JM, Machado JC, et al. Utilidad del diagnóstico molecular en una familia con síndrome de Marfan y un fenotipo vascular atípico. *Rev Esp Cardiol.* 2011;64:151–4.
2. Immer FF, Bansi AG, Immer-Bansi AS, McDougall J, Zehr KJ, Schaff HV, et al. Aortic dissection in pregnancy: analysis of risk factors and outcome. *Ann Thorac Surg.* 2003;76:309–14.
3. Tomihara A, Ashizawa N, Abe K, Kinoshita N, Chihaya K, Yonekura T, et al. Risk of development of abdominal aortic aneurysm and dissection of thoracic aorta in a postpartum woman with Marfan's syndrome. *Intern Med.* 2006;45:1285–9.
4. Groenink M, Lohuis TA, Tijssen JG, Naeff MS, Hennekam RC, Van der Wall EE, et al. Survival and complication free survival in Marfan's syndrome: implications of current guidelines. *Heart.* 1999;82:499–504.
5. Nollen GJ, Groenink M, Tijssen JG, Van Der Wall EE, Mulder BJ. Aortic stiffness and diameter predict progressive aortic dilatation in patients with Marfan syndrome. *Eur Heart J.* 2004;25:1146–52.
6. Expert Consensus Document on Management of Cardiovascular Diseases During Pregnancy. The Task Force on the Management of Cardiovascular Diseases During Pregnancy of the European Society of Cardiology. *Eur Heart J.* 2003; 24:761–81.

doi: 10.1016/j.rec.2011.04.023

## P Wave Morphology and Recurrence After Cardioversion of Lone Atrial Fibrillation

### Morfología de la onda P y recurrencia tras cardioversión de fibrilación auricular aislada

#### To the Editor,

Approximately 30%–60% of patients who undergo cardioversion for atrial fibrillation (AF) suffer a recurrence (R-AF) in the mid-term.<sup>1</sup> Among the different variables associated with R-AF, dilation of the left atrium (LA)<sup>2,3</sup> is probably among the best known. Little information exists, however, on the capacity of the morphology of the P wave to predict the probability of R-AF. The P wave reflects the electrical depolarization of the atrium. When it is biphasic in the precordial V1 lead, the negative terminal portion represents the electrical activation of the LA.<sup>4</sup> An increase in its magnitude is associated with an increase in the volume of the LA, a delay in

conduction, or both. We aimed to determine whether the presence of a negative terminal deflection of the P wave in V1 of  $\geq 0.1$  mV and lasting  $\geq 40$  ms (NTDV1) distinguishes patients at greater risk of R-AF following cardioversion for lone AF of recent onset (Fig. 1).

Between January 2006 and March 2007, we undertook a prospective study of 146 consecutive patients with lone AF of recent onset (<48 h) that was reverted to sinus rhythm (SR) at our center: in 61 patients (42%) the AF episode ended spontaneously; 85 patients (58%) required either electrical (n = 38) or pharmacological cardioversion (n = 47). No patient suffered ventricular dysfunction nor any significant valve disease. Table 1 shows the baseline characteristics of the patient population. Follow-up was undertaken for one year. R-AF was defined as a clinical recurrence (the perception of an arrhythmic pulse lasting more than 1 min) or an electrocardiographic recurrence detected during programmed or additional appointments during follow-up.

All calculations were performed using SPSS/PC v.17 software (SPSS Inc.; Chicago, Illinois, United States). Continuous variables

**Table 1**  
Univariate Analysis of the Predictors of Recurrent Atrial Fibrillation (Log Rank Test)

Variable	Value for the entire sample, no. (%)	R-AF (%) <sup>a</sup>	Log rank ( $\chi^2$ )	P
Age >75 years	40 (27)	40 vs 56	0.43	.51
Men	93 (53)	56 vs 59	0.11	.74
High blood pressure	90 (61)	57 vs 57	0	1
Diabetes mellitus	21 (14)	52 vs 58	0.62	.43
Persistent AF	85 (58)	59 vs 56	1.16	.28
Treatment with anti-arrhythmia medication <sup>b</sup>	56 (38)	50 vs 62	1.51	.22
ACEI/ARB-II	77 (53)	55 vs 61	1.54	.22
Creatinine clearance <60 ml/min	18 (12)	78 vs 55	6.92	.01
Area of LA $\geq 20$ cm <sup>2</sup>	85 (54)	65 vs 48	6.8	.01
NTDV1	65 (44)	72 vs 46	11.55	.001

ACEI, angiotensin converting enzyme inhibitors; AF, atrial fibrillation; ARB-II, angiotensin II AT1 receptor antagonists; LA, left atrium; NTDV1, negative terminal deflection of the P wave in V1 of  $\geq 0.1$  mV lasting  $\geq 40$  ms; R-AF, recurrent atrial fibrillation.

<sup>a</sup> Percentage of patients with recurrent AF after cardioversion (present vs absent).

<sup>b</sup> Twenty-eight patients were treated with amiodarone and 28 with flecainide.