

Image in cardiology

A Spontaneous Coronary Dissection Successfully Treated With Bioabsorbable Scaffolds



Diseción coronaria espontánea tratada con armazones bioabsorbibles

M. Rosario Ortas-Nadal,* Isaac Pascual, and Cristina Moreno-Ambroj

Unidad de Hemodinámica y Cardiología Intervencionista, Servicio de Cardiología, Hospital Universitario Arnau de Vilanova, Lérida, Spain

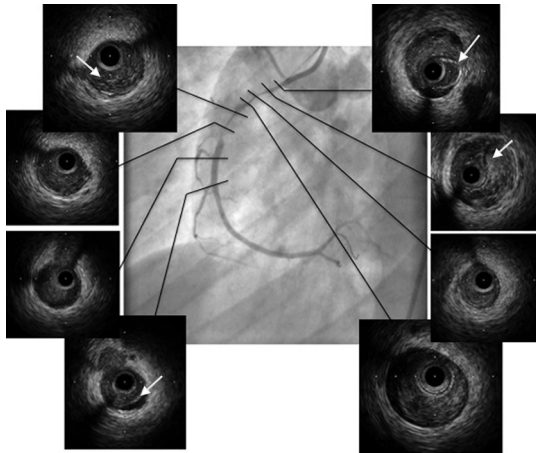


Figure 1.

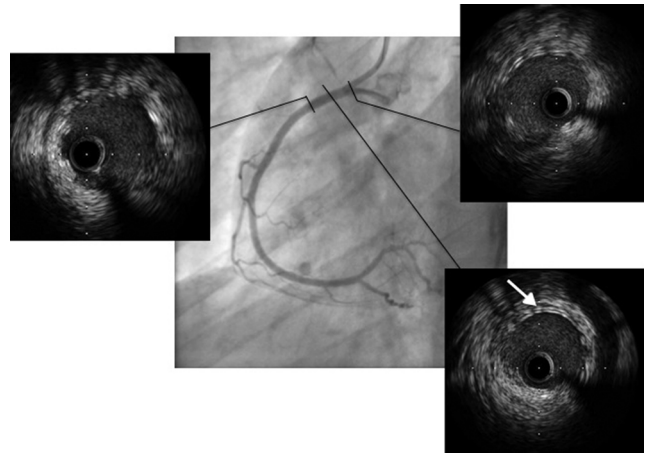


Figure 2.

A 36-year-old female patient with no relevant medical history was admitted for non-ST segment elevation infarction. The emergency coronary angiography showed long, subocclusive disease of the proximal-medial segment of the right coronary artery, affecting the distal flow (TIMI 2) (Figure 1). The angiographic image showed atherosclerosis, but the intravascular echocardiography identified a large intramural haematoma with detachment of the tunica intima, confirming the diagnosis of spontaneous dissection (Figure 1, arrows). Two overlapping bioabsorbable scaffolds were implanted in tandem measuring 3×28 and 3.5×28 mm (0.5 mm difference in diameters), with complications. The angiographic result was good, confirmed by intravascular echocardiography (Figure 2).

Spontaneous coronary dissection is a cause of acute coronary syndrome, with a low incidence but high mortality, which usually affects young women and is occasionally related to different clinical contexts, such as pregnancy or therapy with oral contraceptives. Intravascular echocardiography is a good complement to coronary angiography for confirming the diagnosis.

Treatment of this endovascular condition is controversial and is based on a conservative strategy and coronary revascularisation (percutaneous and/or surgical) only when symptoms persist and the distal perfusion of the vessel is affected.

The use of new bioabsorbable scaffolds in this context could be a good therapeutic option for young patients, such as in the case reported here, with no underlying atherosclerotic disease, which could allow for complete functional recovery of the vessel treated in the future.

A check-up of the artery treated in 2 years' time and the absorption time of the scaffolds could complete the information reported in this case.

* Corresponding author:

E-mail address: charortasnadal@gmail.com (M.R. Ortas-Nadal).

Available online 2 March 2015