

## A New Classification of Coronary Bifurcation Lesions

### To the Editor:

Coronary lesions located at a bifurcation present a wide range of angiographic and anatomical morphologies depending upon the distribution of the plaque in the segment affected.

Different classifications have been proposed and used to define these lesions.<sup>1-3</sup> Although these classifications clearly define all the possible combinations, they are difficult to memorise. For our classification we use the 3 components of a bifurcation: the main branch proximal (MBP), the main branch distal (MBD), and the side branch (SB). Respecting that sequence, we propose a new simple intuitive classification which does not demand memorisation. It consists in giving a binary value (1, 0) according to whether each of the segments previously defined is compromised or not. Figure shows the 7 possible morphologies.

We consider that this new approach, compared to previous classifications, makes the description of the anatomy of coronary bifurcations much more simple, a factor which is technically and strategically significant when facing percutaneous treatment and assessing its results.

Likewise, it could also facilitate the inclusion of descriptive parameters in the data base which analyses the result of percutaneous treatment of bifurcations.

Last, we consider that it allows for homogenous terminology when comparing different series and techniques.

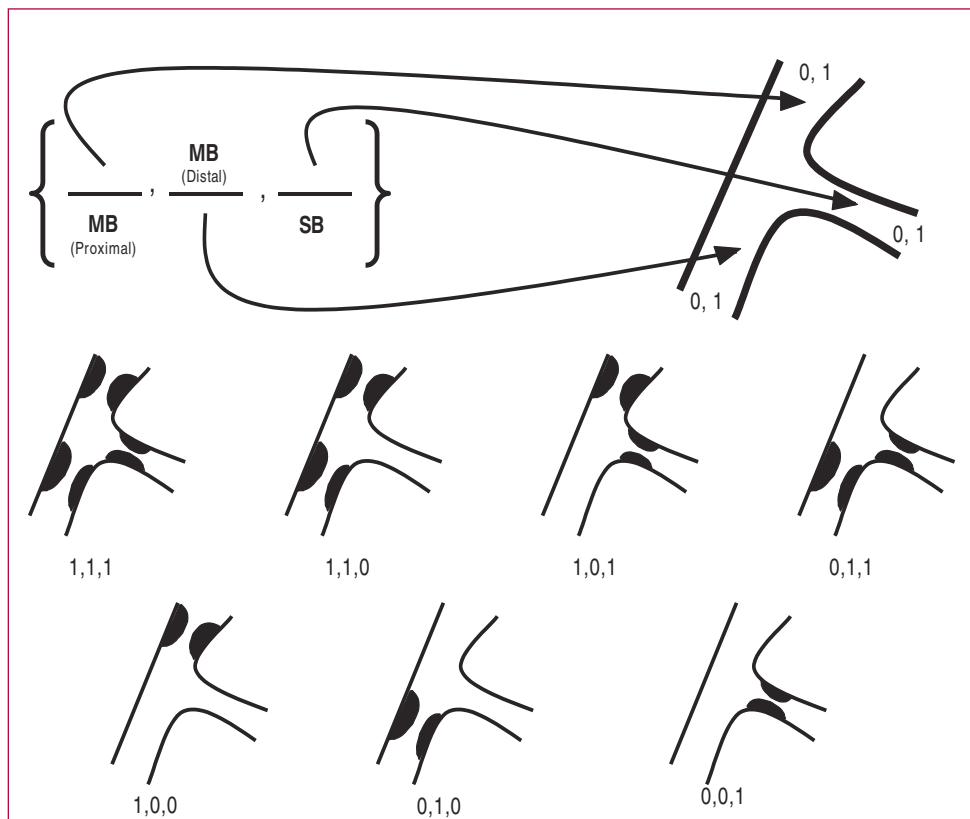
Alfonso Medina,<sup>a</sup> José Suárez de Lezo,<sup>b</sup>  
and Manuel Pan<sup>b</sup>

<sup>a</sup>Servicio de Cardiología, Hospital Doctor Negrín,  
Universidad de Las Palmas de Gran Canaria,  
Las Palmas de Gran Canaria, Spain.

<sup>b</sup>Servicio de Cardiología, Hospital Reina Sofía,  
Universidad de Córdoba, Córdoba, Spain.

### REFERENCES

1. Pompa J, Bashore T. Qualitative and quantitative angiography—Bifurcation lesions. In: Topol E, editor. Textbook of interventional cardiology. Philadelphia: W.B. Saunders; 1994. p. 1055–8.
2. Lefevre T, Louvard Y, Morice MC. Stenting of bifurcation lesions: Classification, treatments, and results. *Cathet Cardiovasc Intervent*. 2000;49:274–83.
3. Safian RD. Bifurcation lesions. In: Safian RD, Freed M, editors. Manual of interventional cardiology. Royal Oak: Physicians' Press; 2001. p. 221–36.



**Figure.** A new classification of coronary bifurcation lesions.